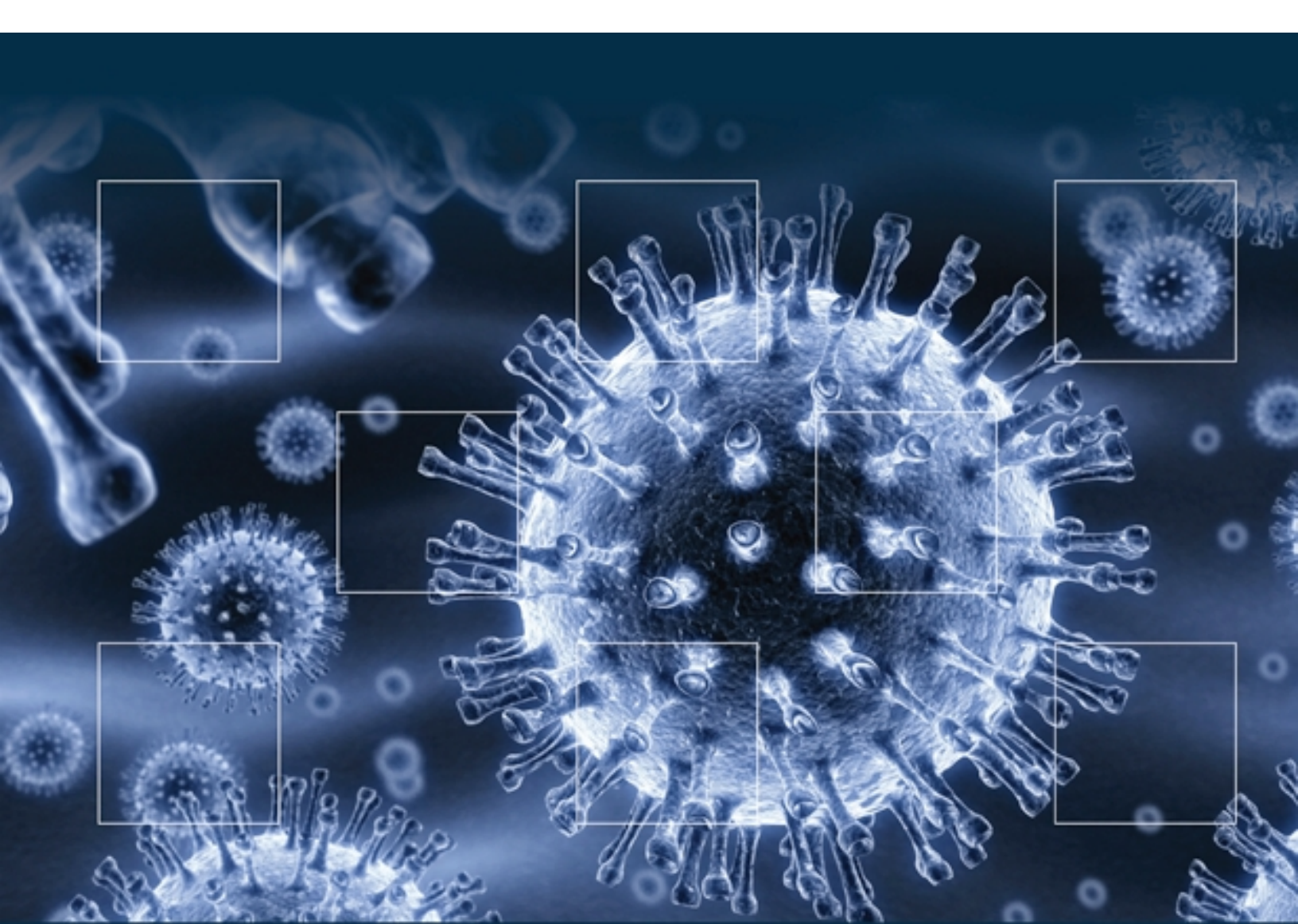

*Remington and Klein's*  
**INFECTIOUS DISEASES  
OF THE FETUS AND  
NEWBORN INFANT**

*Eighth Edition*

Wilson, Nizet, Maldonado, Remington, Klein

ELSEVIER  
SAUNDERS

# 10

## Focal Bacterial Infections

GARY D. OVERTURF, MARTHA MULLER, and VICTOR NIZET

### CHAPTER OUTLINE

#### Infections of the Liver

Microbiology  
Pathogenesis  
Clinical Manifestations  
Diagnosis  
Prognosis  
Treatment

#### Splenic Abscess

#### Infections of the Biliary Tract

#### Infections of the Adrenal Glands

#### Appendicitis

Microbiology  
Pathogenesis  
Clinical Manifestations  
Diagnosis  
Prognosis  
Treatment

#### Peritonitis

Microbiology  
Pathogenesis  
Clinical Manifestations  
Diagnosis  
Prognosis  
Treatment

#### Necrotizing Enterocolitis

#### Pathology and Pathogenesis

Microbiology  
Clinical Manifestations  
Diagnosis  
Treatment  
Prevention  
Prognosis

#### Endocarditis

#### Pericarditis

#### Mediastinitis

#### Esophagitis

#### Infections of Endocrine Organs

#### Infections of the Salivary Glands

#### Infections of the Skin and Subcutaneous Tissue

Pathogenesis  
Microbiology  
Epidemiology  
Clinical Manifestations  
Diagnosis  
Differential Diagnosis  
Treatment  
Prevention

#### Conjunctivitis and Other Eye Infections

### Infections of the Liver

Bacterial infection of the hepatic parenchyma frequently is recognized as multiple, small inflammatory foci (hepatic microabscesses) observed as an incidental finding in infants dying with sepsis. Diffuse hepatocellular damage, often in conjunction with infection of several organ systems, may be present after transplacental passage of microorganisms to the fetal circulation. Liver involvement rarely may take the form of a solitary purulent abscess. Metastatic focal infections of the liver associated with bacteremia resolve with antimicrobial therapy, are not recognized, or are found only at postmortem examination. Rarely, they are clinically apparent as solitary<sup>1</sup> or multiple<sup>2</sup> large abscesses diagnosed during life.

Although metastatic infections are rare, it is difficult to ascertain their true incidence. In a survey of more than 7500 autopsies of children performed from 1917 to 1967, Dehner and Kissane<sup>3</sup> found only 3 neonates with multiple, small, pyogenic hepatic abscesses, whereas a review of approximately 4900 autopsies performed at Los Angeles

Children's Hospital from 1958 to 1978 revealed 9 infants with pyogenic hepatic abscesses.<sup>4</sup> Among 175,000 neonates admitted from 1957 to 1977 to Milwaukee Children's Hospital, 2 died with hepatic microabscesses<sup>5</sup>; 3 patients with hepatic microabscesses were seen among 83,000 pediatric patients admitted to New York Hospital from 1945 to 1983.<sup>6</sup>

Solitary hepatic abscesses in newborns have also been reported rarely.<sup>1,2,4</sup> These infections frequently are associated with prematurity and umbilical vein catheterization,<sup>4,5</sup> or because of bacteremia, for instance, after sepsis caused by *Staphylococcus aureus*.<sup>1</sup>

### MICROBIOLOGY

Etiologic agents in the infants described by Dehner and Kissane,<sup>3</sup> Moss and Pysher,<sup>4</sup> Chusid,<sup>5</sup> and Simeunovic and colleagues<sup>7</sup> have included *Escherichia coli*, *S. aureus*, *Pseudomonas aeruginosa*, *Klebsiella* spp., *Enterobacter* spp., *Neisseria gonorrhoeae*, and *Listeria monocytogenes*. The causative bacteria of solitary abscesses are generally the bacteria colonizing the umbilical stump,<sup>8</sup> including *S. aureus*

(most common), *E. coli*, *Enterobacter* spp., *Klebsiella pneumoniae*, *P. aeruginosa*, and *Streptococcus pyogenes*. The observation of gas in abscesses<sup>9,10</sup> may indicate infection with anaerobes, a frequent cause of liver abscess in adults.<sup>11</sup>

The most common cause of intrauterine bacterial hepatitis, congenital listeriosis, characteristically involves the liver and adrenals (see Chapter 13). Typical lesions are histologically sharply demarcated areas of necrosis (miliary granulomatosis) or microabscesses containing numerous pleomorphic gram-positive bacilli.<sup>12</sup> Intrauterine tuberculosis results from maternal bacillemia with transplacental dissemination to the fetal bloodstream (see Chapter 18). Because the liver is perfused by blood and well oxygenated<sup>13</sup> and is the first organ that encounters tubercle bacilli, it is often severely involved.<sup>12,14</sup> The presence of primary liver foci is considered evidence for congenital tuberculous infection as a result of hematogenous spread through the umbilical vein.<sup>15</sup> Closed-needle biopsy may be less accurate in the diagnosis of hepatic granulomas, and open biopsy may be required to confirm liver and regional node involvement.<sup>16</sup> In addition to hepatomegaly, a clinical picture of fever with elevated serum immunoglobulin M (IgM) and chorioretinitis (e.g., choroid tubercles) may be similar to that caused by other congenital infectious agents.<sup>17</sup> In a review by Abughal and coworkers,<sup>17</sup> positive sites of culture for tuberculosis included liver (8 of 9), gastric aspirate (18 of 23), tracheal aspirate (7 of 7), ear (5 of 6), and cerebrospinal fluid (3 of 10).

*Treponema pallidum* is the spirochete most commonly associated with transplacental hepatic infection (see Chapter 16). Pathologic changes in the liver, which may be found in 95% of infants dying with congenital syphilis,<sup>18</sup> include diffuse hepatitis or focal areas of inflammation, both frequently accompanied by increased connective tissue and enlargement of the liver.<sup>18,19</sup> Involvement of liver has also been documented, on the basis of isolation of organisms or their identification in histologic sections, in newborns with intrauterine infection caused by various *Leptospira* spp.<sup>20,21</sup> Transplacental infection of the fetus with *Borrelia recurrentis* causes little or no inflammation of liver parenchyma or biliary epithelium despite the presence of numerous spirochetes in the sinusoids.<sup>22,23</sup>

With increasing use of broad-spectrum antibiotics, candidal sepsis has emerged as a serious complication in newborn intensive care units, and liver abscesses can develop during the course of disseminated infection.<sup>24</sup> Use of umbilical venous catheters and total parenteral nutrition was reported in the majority of such cases.

## PATHOGENESIS

Infectious agents may reach the liver of the fetus or newborn by one of several pathways: transplacental or transoral intrauterine infection; extension of thrombophlebitis of the umbilical vein, through the hepatic artery during the course of a systemic bacteremia; pyelophlebitis caused by a focus of infection in the drainage of the portal vein (mesenteric or splenic veins); direct invasion from contiguous structures or because of trauma or surgical inoculation; and extension up the biliary passages in cases of suppurative cholangitis. Abscesses with no apparent focus of

infection seem to be common in newborns compared with older children.<sup>25</sup> In one such case of solitary liver abscess, the nature of the lesion suggested that an umbilical vein infection, obscured by the large collection of purulent material in the abscess, was the probable pathogenesis.<sup>26</sup>

The mode of infection usually determines the pattern of hepatic involvement. Intense and prolonged seeding of the liver parenchyma, such as that which occurs in conjunction with intrauterine infection or neonatal sepsis, almost invariably results in diffuse hepatocellular damage or multiple small inflammatory lesions.<sup>3-5</sup> Umbilical vein thrombophlebitis may cause an abscess of the falciform ligament<sup>27</sup> or extend into a single branch of the portal vein to produce a solitary pyogenic abscess,<sup>5,28,29</sup> or it can lead to disseminated foci of infection through dislodgment of septic emboli.<sup>5,30</sup>

The frequent use of umbilical catheters has been associated with an increase in the numbers of infants with solitary<sup>4,5,28,29,31</sup> or multiple<sup>4,32,33</sup> hepatic abscesses. In three large series, including almost 500 infants who died after placement of umbilical vein catheters, 29 infants were found to have purulent infections of hepatic vessels or parenchyma.<sup>33-35</sup> Use of venous catheters for infusion of hypertonic or acidic solutions may provide a necrotic focus for abscess formation,<sup>28,31,32,35,36</sup> and prolonged or repeated<sup>4,29,31,35</sup> catheterization of a necrotic umbilical stump provides an ideal pathway for introduction of pathogenic organisms.

Although neonatal liver abscesses usually are caused by hematogenous dissemination of bacteria through the hepatic artery or umbilical vein, examples of infection arising from various other sources have been described. Solitary abscesses have followed a presumed portal vein bacteremia caused by amebic colitis.<sup>37,38</sup> Direct invasion of adjacent liver parenchyma from purulent cholecystitis<sup>39</sup> or postoperative perihepatic abscesses<sup>4</sup> also has been observed. Ascending cholangitis, the most frequent cause of hepatic purulent infections in adults,<sup>25</sup> has not been implicated in the causes of newborn infections.

Descriptions of “umbilical sepsis” and “acute interstitial hepatitis” recorded by Morison<sup>40</sup> seem to indicate that his patients had acquired bacterial infections of umbilical vessels with widespread extension into portal tracts. Although mild periportal parenchymal necrosis was observed in a few infants, hepatocellular damage was minimal or absent in most. Similar lesions have been found in infants dying with sepsis<sup>41</sup> and infantile diarrhea.<sup>42</sup>

## CLINICAL MANIFESTATIONS

Multiple hepatic abscesses and diffuse hepatitis related to neonatal sepsis or transplacental fetal infection are usually recognized only at autopsy. Very few clinical manifestations referable to hepatocellular damage are evident before death. The signs and symptoms associated with these conditions are those of the underlying sepsis or of secondary metastatic complications, such as meningitis, pneumonitis, or peritonitis. Solitary abscesses are indolent in terms of their development and clinical presentation. Although the suppurative umbilical focus or umbilical catheterization responsible for the introduction of microorganisms can usually be traced to the first week of life, evidence of hepatic involvement is usually not apparent before the second or third week. The abscess



frequently becomes a source for the hematogenous dissemination of microorganisms so that most infants have signs and symptoms of a bacteremia. Despite intense infection of the underlying vessels, the umbilical stump usually shows no evidence of inflammation or purulent discharge. The presence of hepatomegaly, a finding commonly associated with neonatal sepsis, also offers little aid in establishing a definitive diagnosis. In one half of infants for whom physical findings are clearly described, a well-delineated, often fluctuant or tender mass could be palpated in the epigastrium or right upper quadrant. On a few occasions, the infant's mother noticed a mass, often several days before the onset of systemic symptoms. Abscesses occur in the right or left lobe of the liver with almost equal frequency and are generally 3 cm or greater in diameter at the time of surgical exploration.

## DIAGNOSIS

Hematologic studies are of little value in establishing a diagnosis; leukocyte counts and sedimentation rates may be normal or elevated. The serum levels of liver enzymes may also be normal<sup>43</sup> or elevated.<sup>4,44</sup> Abdominal radiographs are usually normal or show nonspecific displacement of the lower edge of the liver. In five infants, diagnosis was suspected from plain radiographs by the presence of gas within the hepatic shadow.<sup>31,45</sup> Radiologic findings that commonly accompany hepatic abscess in older children, such as an altered contour of the diaphragm, right pleural effusion, and platelike atelectasis,<sup>46</sup> are rarely present in neonates.

Ultrasonography should be the initial imaging study in newborns with clinical evidence of a hepatic abscess.<sup>47,48</sup> If ultrasonography is negative and the diagnosis is still strongly suspected, more sensitive techniques, such as computed tomography (CT) or magnetic resonance imaging (MRI), should be performed.<sup>48-50</sup> Enhancement with contrast agents may increase the definition of smaller abscesses. Because congenital cysts, arteriovenous malformations, and tumors with central necrosis or hemorrhage can mimic hepatic abscess, the diagnosis should always be confirmed by aspiration of purulent material at laparotomy or by means of percutaneous drainage with ultrasound or CT guidance.<sup>51-54</sup>

## PROGNOSIS

The prognosis for infants with diffuse liver involvement related to fetal or neonatal sepsis depends on the underlying condition because hepatic function is rarely compromised sufficiently to determine the outcome. In most cases, pathologic changes in the liver are unsuspected before postmortem examination.

Of 28 infants with solitary hepatic abscesses whose course was described, 6 died. Four newborns died with sepsis caused by organisms that were identical to the organisms isolated from the abscess,<sup>28,43,55,56</sup> and the death of another was ascribed to cecal perforation.<sup>38</sup> Prematurity was undoubtedly a major contributing factor in two of these deaths.<sup>28,43</sup>

## TREATMENT

Newborns with a solitary hepatic abscess have traditionally been treated with open surgical drainage in conjunction with antibiotic therapy. Percutaneous catheter drainage

is less invasive and often is the preferred first treatment. Several investigators have described the use of percutaneous drainage of intrahepatic abscesses and cysts, guided by CT or ultrasonography, in neonates.<sup>8,33,53</sup> When combined with antibiotic therapy and monitored by ultrasonography to ensure resolution, this treatment has been highly effective. It is questionable whether drainage contributed to recovery other than by aiding the selection of antibiotic coverage. Subsequently, patients have been successfully treated with empirical antibiotic therapy alone.<sup>57-59</sup>

The risk of bacteremia and disseminated infection is high in neonates, and the need to identify infecting organisms to guide antibiotic coverage is of greater urgency in the first weeks of life. It is appropriate to ascertain a microbiologic diagnosis with radiographically guided aspiration or drainage of hepatic abscess in a newborn. When proper equipment (e.g., CT, ultrasonography) and experienced personnel are available, this can be attempted percutaneously.<sup>52,53</sup> When they are unavailable, open surgical drainage should be performed. Empirical antibiotic therapy should be reserved only for infants for whom it is believed that the risk of open or closed drainage would exceed the potential benefits.

If purulent material is obtained, initial antibiotic therapy can be selected on the basis of Gram stain. In addition to *S. aureus* and the aerobic enteric organisms commonly associated with hepatic abscesses, anaerobic bacteria have been suspected as the cause of infection in numerous patients. If foul-smelling pus is aspirated or if Gram-stained smears show organisms with the characteristic morphology of anaerobes, metronidazole,  $\beta$ -lactam and  $\beta$ -lactamase inhibitor combinations (e.g., piperacillin and tazobactam), clindamycin, or imipenem should be included in the initial regimen. Cultures of blood, cerebrospinal fluid, and urine should also be considered before initiation of therapy.

If empirical antibiotic therapy is required, it must be adequate for infections caused by *S. aureus*, enteric organisms, and anaerobic bacteria. The combination oxacillin, gentamicin, and clindamycin is appropriate. In nurseries where methicillin-resistant *S. aureus* (MRSA) or methicillin-resistant *Staphylococcus epidermidis* infections have been a problem, substitution of vancomycin for oxacillin can provide coverage for these organisms. Gentamicin (and other aminoglycosides) and vancomycin levels must be monitored and dosages adjusted as necessary. Extended-spectrum cephalosporins (e.g., cefotaxime, cefepime, ceftazidime) and carbapenems (e.g., meropenem) may be used for enteric organisms and *Pseudomonas* spp., often obviating the need for aminoglycosides.  $\beta$ -Lactam and  $\beta$ -lactamase inhibitor combination drugs (e.g., piperacillin and tazobactam or ampicillin and sulbactam) may provide coverage for many enteric organisms and anaerobic bacteria.

Definitive therapy is based on results of bacteriologic cultures that identify the bacteria and its antibiotic susceptibility. Adequate anaerobic transport and culture techniques must be available if meaningful information is to be obtained. Duration of treatment is based on clinical response, cessation of drainage, and resolution of the abscess cavity as determined by serial ultrasound examinations. Parenteral therapy should be maintained for at least 2 weeks, and longer-term therapy may be administered when necessary. In older children with multiple abscesses

or in children for whom surgery is not feasible, therapy for 6 weeks or more has been recommended.

## Splenic Abscess

Similar to hepatic abscesses, splenic abscesses have been rarely described in infants.<sup>60</sup> Only 1 of 55 splenic abscesses occurred in an infant younger than 6 months. *S. aureus*, *Candida* spp., and streptococci were the most frequent causes. In 20 of 48 cases, hepatic abscesses coexisted with splenic abscess. In the single infant case, torsion of the splenic vessels was present, whereas in older children, other distant infections of hematologic conditions (e.g., hemoglobinopathy, hematogenous malignancy) were the associated comorbid conditions. Rare etiologies of splenic abscess reported in the neonatal period include tuberculosis,<sup>61</sup> with accompanying thrombocytopenia, and *Entamoeba histolytica*, complicated by fatal colonic perforation.<sup>62</sup>

## Infections of the Biliary Tract

The development of ultrasonography has provided a safe and rapid means for evaluating the neonatal biliary tract. Consequently, an increasing number of reports have appeared describing ultrasound changes seen in the first month of life, with hydrops,<sup>63</sup> cholelithiasis,<sup>64-67</sup> and transient distention of the gallbladder associated<sup>63,66,68-70</sup> or unassociated<sup>66,69-71</sup> with sepsis. Ultrasound criteria for separating normal from pathologically enlarged gallbladders and biliary tracts in neonates have also been described.<sup>72,73</sup>

Despite advanced technology and increased surveillance, cholecystitis in the neonate is observed infrequently. The literature has documented a few dozen cases, of which 9 were seen in association with an epidemic of neonatal enteritis caused by *Salmonella enteritidis*.<sup>74</sup> Two cases of acute necrotizing cholecystitis caused by *E. coli* infection were described in a preterm and term neonate.<sup>75</sup> The pathogenesis of this condition is uncertain; and the great majority of cases in the newborn period have been acalculous. It is postulated that sepsis, dehydration, prolonged fasting (e.g., total parenteral nutrition), congenital obstruction, or a stone impacted in the cystic duct leads to biliary stasis and acute distention of the gallbladder. In most cases, resolution of the primary process permits restoration of the flow of bile and relief of distention. In some cases, prolonged obstruction leads to hydrops.<sup>63</sup> Cholecystitis rarely follows, perhaps because of a direct toxic effect of retained bile or because of ischemia related to elevated intraluminal pressure. Bacterial invasion by fecal flora is probably a secondary phenomenon.<sup>76,77</sup> Other organisms that have been isolated from gallbladder contents or tissue include *Serratia marcescens*, *Pseudomonas* spp., *Enterococcus faecalis*, viridans streptococci, *S. aureus*, and *Clostridium welchii*.

Infants with cholecystitis may become ill at any time during the first weeks of life; most cases are diagnosed in the third or fourth week. The typical clinical picture is one of sepsis together with signs of peritoneal inflammation and a palpable tender right upper quadrant or epigastric mass. Diarrhea frequently accompanies these findings. Although ultrasonography and radionuclide scintigraphy are helpful

in suggesting the presence of gallbladder enlargement or inflammation, diagnosis can be confirmed only by surgical exploration.<sup>63,69</sup> Treatment consists of cholecystectomy or tube cholecystostomy combined with systemic antimicrobial therapy based on Gram stain, culture, and susceptibility studies. If a T tube is placed in the gallbladder, a cholangiogram should be obtained to confirm patency of the biliary system before the tube is removed.

Changes compatible with a diagnosis of ascending cholangitis have been described in histologic sections of liver specimens from infants who died with diarrhea accompanied by hepatocellular injury with cholestasis.<sup>57</sup> Bacteria were also identified in the biliary tree of 2 of 178 premature infants who died after placement of an umbilical venous catheter for an exchange transfusion or for delivery of parenteral fluids.<sup>33</sup> The reasons for this association, if any, are unclear. An infant with spontaneous cholangitis caused by *Enterobacter agglomerans*, presenting as a fever of unknown origin at 3 weeks of age, has also been reported.<sup>78</sup> Severe inflammation and fibrosis of extrahepatic bile ducts and diffuse changes in the portal tracts, resembling changes found in biliary atresia, were found in a premature infant who died 3 hours after birth of listeriosis.<sup>79</sup> The investigator postulated that occult prenatal infections with *L. monocytogenes* might be a rare cause of ascending cholangitis manifesting as idiopathic biliary atresia at birth.

## Infections of the Adrenal Glands

Multiple adrenal microabscesses are occasionally found as metastatic lesions associated with neonatal sepsis. These abscesses are particularly characteristic of neonatal listeriosis (see Chapter 13). Solitary adrenal abscesses are rare, however; only a few dozen such cases have been described.<sup>9,80</sup> The spectrum of organisms responsible for adrenal abscesses is the same as that seen in neonatal sepsis and includes *E. coli*,<sup>9,81,82</sup> group B streptococci (GBS),<sup>83,84</sup> *Proteus mirabilis*,<sup>85</sup> *S. aureus*,<sup>86</sup> *Bacteroides* spp.,<sup>87</sup> and *Peptostreptococcus*.<sup>88</sup>

About three fourths of neonatal cases are male, and adrenal abscesses are more commonly located on the right side (approximately two thirds of patients); bilateral lesions are uncommon.<sup>80,83,89,90</sup> The same sex and laterality predominance are seen with adrenal hemorrhage in the newborn,<sup>90</sup> and it has been postulated that formation of an adrenal abscess requires a preexisting hematoma as a nidus for bacterial seeding.<sup>89</sup> This theory of pathogenesis is supported further by clinical observations and by objective evidence (e.g., curvilinear calcifications) documenting the presence of hemorrhage before development of an abscess.<sup>86,87,89</sup>

Most infants with adrenal abscess have presented in the third or fourth week of life with signs of sepsis and an abdominal or flank mass. A history of difficult delivery or intrapartum asphyxia was observed in about one half of these infants, and significant maternal fever or infection during labor was observed in about one fourth.<sup>84,89</sup> Although a few infants are afebrile when first evaluated, a palpable mass is almost always present. Abscesses are usually 6 to 8 cm in diameter, with some containing 200 mL of pus<sup>91</sup> and measuring 12 cm in diameter<sup>91</sup> or crossing the midline.<sup>87</sup>

Laboratory studies are helpful in the evaluation of a possible adrenal abscess. Most infants exhibit a leukocytosis; about one third are anemic and with a history of prolonged neonatal jaundice, both of which are features associated with adrenal hemorrhage. Urinary excretion of catecholamines and their metabolites (particularly vanillylmandelic acid and homovanillic acid), which is usually increased with neuroblastoma, is normal. Because most infants with adrenal abscess are seen for evaluation of possible sepsis, a blood culture, lumbar puncture, urine culture, and chest radiograph should be obtained.

Ultrasonography has become a widely accepted modality for initial evaluation of all neonatal abdominal masses. With the presence of an adrenal abscess, ultrasound examination can help to define the extent and cystic nature of the lesion and often can show movable necrotic debris in the abscess cavity.<sup>86-89</sup>

With serial examinations, abscesses can be distinguished from masses associated with liquefying hematoma, adrenal cyst, hydronephrosis of an obstructed upper pole duplication, or necrotic neuroblastoma.<sup>60,84,89,92</sup> Intravenous pyelography shows downward displacement of the kidney and compression of the upper calyces, which confirms the presence of a suprarenal mass.<sup>82,86-89</sup> A round, suprarenal, radiopaque halo or rim with central lucency, which is characteristic of adrenal abscess, may also be seen on early films<sup>83</sup> but is not pathognomonic.<sup>89</sup> Intravenous pyelography adds little diagnostic information to that provided by ultrasound studies. Experience with radionuclide scanning, CT, and MRI in this condition is limited, but these modalities are likely to be as useful as ultrasonography.<sup>84,86,89</sup>

Whatever diagnostic methods are used, concern about persisting signs of sepsis and the possible presence of an adrenal neoplasm usually encourage early efforts to establish a diagnosis. In the past, recommended management has been incision and drainage or resection of the abscess.<sup>89,92,93</sup> Needle aspiration under ultrasound guidance, combined with placement of a catheter for drainage and irrigation, has proved to be a useful alternative method<sup>85,94</sup> and is likely to supplant open drainage as the preferred method. Antibiotic therapy should be based on Gram stain, culture, and susceptibility studies of abscess fluid and should be continued for 10 to 14 days, provided that drainage can be established.

The adrenals are infected in about 15% of infants with congenital syphilis.<sup>18</sup> In addition to the presence of spirochetes, the most frequent and characteristic change is an extraordinary amount of cellular connective tissue in the capsule.

## Appendicitis

Acute appendicitis is extremely rare in infants younger than 4 weeks of age. Reviews of more than 25,000 cases of appendicitis in infants and children in Great Britain,<sup>95</sup> Ireland,<sup>96</sup> Germany,<sup>97</sup> and the United States<sup>98-104</sup> revealed only 8 infants who presented during the neonatal period. Since the condition was first described by Albrecht in 1905<sup>105,106</sup> and Diess in 1908,<sup>107</sup> sufficient cases of neonatal suppurative appendicitis have been reported in the literature details that permit characterization of the clinical

features.<sup>98,99,101,108-131</sup> Infants with appendicitis caused by other conditions, such as Hirschsprung disease,<sup>132</sup> necrotizing enterocolitis (NEC),<sup>133</sup> or incarceration in an inguinal hernia,<sup>134</sup> have not been included in this discussion.

Inflammation of the appendix is more common in newborn boys than newborn girls. In reports in which the sex was stated, 40 cases occurred in boys, and 17 cases occurred in girls. Prematurity also seems to be a predisposing factor: 23 of the 49 infants whose birth weights were recorded weighed less than 2500 g at birth. The incidence of appendicitis in infants of multiple births (six twins and one triplet) seems to be higher than would be expected on the basis of low birth weight alone.

Although rare, neonatal appendicitis is likely to occur with greater frequency, as perinatal conditions associated with appendicitis, such as prematurity and survival after severe hypoxia, are increasingly common with advances in neonatal care.<sup>135</sup>

## MICROBIOLOGY

Because obstruction of the appendiceal lumen is responsible for almost all cases of appendicitis,<sup>135</sup> it is intuitive that gram-negative enteric organisms resident in the bowel are usually isolated from the peritoneal fluid or periappendiceal pus of about 75% of infants. Specific etiologic agents include *E. coli*, *Klebsiella* spp., *Enterobacter* spp., *Pseudomonas* spp., *Proteus* spp., untyped streptococci, *S. aureus*, and *Bacteroides* spp. These bacterial species have also been isolated from the peritoneal fluid of older children with appendicitis.<sup>103,136</sup> Attempts at isolation of anaerobic bacteria have been rarely described.

A case of perforated amebic appendicitis with secondary bacterial peritonitis and multiple hepatic abscesses in a premature infant born in Great Britain has been reported. *E. histolytica* observed in the wall of the necrotic appendix was presumably acquired from the infant's father, who was a carrier.<sup>38</sup> A patient with gangrenous appendicitis associated with *Rhizopus oryzae* has also been reported.<sup>137</sup> It was postulated that the fungus colonized the infant's gut by transfer from an adhesive bandage used to secure an endotracheal tube.

## PATHOGENESIS

Obstruction of the appendiceal lumen has been generally accepted as the primary cause of appendicitis in all age groups. The relative rarity of this condition in the first month of life is probably related to factors that serve to decrease the likelihood of obstruction, including a wide-based, funnel-shaped appendix; the predominantly liquid and soft solid diet given to infants; the absence of prolonged periods in the upright position; and the infrequency of infections that cause hyperplasia of the appendiceal lymphoid tissue.<sup>103,138,139</sup> The causes of luminal obstruction in the newborn period, when recognized, are often extrinsic to the appendix itself. Reports of appendicitis caused by the presence of ectopic pancreatic tissue,<sup>98</sup> a fecalith,<sup>108</sup> or meconium plug<sup>104</sup> are unusual exceptions.

Inflammation of the appendix with perforation has been described as the presenting illness in several infants with neonatal Hirschsprung disease.<sup>133,140</sup> The association



of these two conditions has been attributed to functional obstruction, increased intraluminal pressure, and fecal trapping that occur proximal to aganglionic segments. Suppurative appendicitis related to incarceration and strangulation of the cecum within an inguinal or scrotal hernia has been found in numerous infants.<sup>134,141</sup>

## CLINICAL MANIFESTATIONS

The onset of neonatal appendicitis generally occurs during the first 2 weeks of life. Only 3 of 54 infants with this condition presented between the 1st and 10th day. The reasons for this phenomenon are unclear, particularly in view of the relatively even distribution of cases during the remainder of the first year of life.<sup>101</sup> At least five cases of “prenatal” appendicitis have been described.<sup>95,142-145</sup> Of the four available for analysis, only one showed definite evidence of a suppurative process in the appendix and signs of bowel obstruction clearly present at birth<sup>143</sup>; however, cultures and Gram stain of the pus found at surgery were free of bacteria. Poisoning by mercuric chloride was suspected in one<sup>145</sup> of the remaining three cases, and the other two, who were said to have prenatal rupture of the appendix, were asymptomatic until the 2nd<sup>143</sup> and 12th<sup>142</sup> days of life.

The signs of neonatal appendicitis correspond to the signs of any of the various forms of intestinal obstruction that occur during the newborn period (Table 10-1).<sup>142</sup> Prominent early findings include abdominal distention; progressive and frequently bilious vomiting; and evidence of pain, as manifested by persistent crying, irritability, or “colic.” Clinical features such as diarrhea, constipation, lethargy, or refusal to feed may also be evident but are too nonspecific to be helpful in establishing a diagnosis. The presence or absence of fever is an unreliable sign in appendicitis as in other forms of neonatal infection; temperature has been recorded as normal or subnormal in greater than 50% of newborns with this condition. Abdominal tenderness and guarding are inconsistent findings and, when present, are rarely localized to the appendiceal area. Physical signs of sufficient specificity to indicate acute inflammation of the appendix are generally absent until late in the course of the illness, when gangrene and rupture may result in the formation of a localized intraabdominal abscess or cellulitis of

the anterior abdominal wall. Erythema or edema, or both, of the right lower quadrant has been observed in several patients. The presence of this finding, particularly when accompanied by a palpable mass in the right iliac fossa, indicates bowel perforation with peritonitis and should suggest a preoperative diagnosis of NEC or appendicitis (see “Necrotizing Enterocolitis”).

## DIAGNOSIS

The diagnosis of appendicitis in a neonate is usually determined at surgery performed for evaluation of abdominal distention and suspected peritonitis. With the high incidence of prematurity associated with early appendicitis, bowel perforation from NEC has been a common preoperative consideration.<sup>146</sup> The two conditions can coexist, and in some cases, the appendix may participate in the process of ischemic necrosis and perforation.<sup>128,133</sup>

Laboratory studies are of little value in establishing a diagnosis of appendicitis in a newborn. White blood cell counts of less than 10,000/mm<sup>3</sup> were found in 10 of 30 infants. Urinalyses are usually normal, although ketonuria, which reflects diminished caloric intake, and hematuria and proteinuria may be seen. Because bacteremia may accompany appendiceal perforation and peritonitis, a blood culture and evaluation for metastatic infection with lumbar puncture and chest radiography should be performed. The value of paracentesis for diagnosis of bowel perforation and peritoneal infection is discussed later (see “Necrotizing Enterocolitis”).

Radiologic examinations are occasionally helpful but, in most cases, serve only to confirm a clinical impression of small bowel obstruction. The presence of an increased soft tissue density displacing loops of intestine from the right iliac fossa generally indicates appendiceal perforation with abscess formation and is perhaps the most reliable sign of acute appendicitis in the neonate. Extraluminal gas may be localized briefly to the right lower quadrant after rupture of the appendix.<sup>140</sup> The rapid development of an extensive pneumoperitoneum obscures the site of origin of the escaping gas in most infants within a short time.<sup>147</sup> Ultrasonography may aid in detection of a periappendiceal abscess<sup>47</sup> but is not helpful in establishing an early diagnosis of appendicitis because it lacks sensitivity and specificity.

## PROGNOSIS

The overall mortality rate from appendicitis in the newborn is high but is improving. Eight of the newborns in the last 12 reported cases have survived, whereas of 60 infants with this condition for whom the outcome was recorded, 38 (64%) died. Survival was unrelated to birth weight. Among factors responsible for mortalities, three seem to be of primary importance: delay in diagnosis, a high incidence of perforation, and the rapid onset of diffuse peritonitis after appendiceal rupture.

Perforation has been identified at surgery or autopsy in 70% of newborns with acute appendicitis. The relative frequency of this complication has been attributed to delays in establishing a diagnosis and to certain anatomic features of the appendix in young infants that predispose it to early necrosis and rupture. These features include a meager

**Table 10-1** Signs of Intraabdominal Neonatal Appendicitis in 55 Infants

Sign	Incidence (%)
Abdominal distention	90
Vomiting	60
Refusal of feedings	40
Temperature $\geq 38^\circ\text{C}$	40
Temperature $37\text{--}38^\circ\text{C}$	30
Temperature $\leq 37^\circ\text{C}$	30
Pain (crying, restlessness)	30
Lethargy	30
Erythema/edema of right lower quadrant	25
Mass in right lower quadrant	20
Diarrhea	20
Passage of bloody stools	20

blood supply that renders the organ more vulnerable to ischemia; a cecum that is relatively smaller and less distensible than that of adults, forcing a greater intraluminal pressure on the appendix; and the presence of a thin muscularis and serosa that readily lose their structural integrity under the combined effects of ischemia and increased internal pressure.<sup>113,118</sup>

After the appendix ruptures, infants are unable to contain infection efficiently at the site of origin. Rapid dissemination of spilled intestinal contents produces a diffuse peritonitis within hours because of the small size of the infant's omentum, which fails to provide an efficient envelope for escaping material; the relatively longer and more mobile mesenteries, which favor widespread contamination; and the small size of the peritoneal cavity, which also permits access of infected material to areas distant from the site of perforation.<sup>98,113</sup> Peritonitis, accompanied by sepsis and by the massive outpouring of fluids, electrolytes, and proteins from inflamed serosal surfaces, is generally the terminal event in neonatal appendicitis. Deterioration of the infant's condition is often extremely rapid; failure to recognize the underlying illness and to institute appropriate therapy promptly is inevitably followed by a fatal outcome.

## TREATMENT

Surgical intervention is essential for survival of young infants with appendicitis. Because vomiting, diarrhea, and anorexia frequently accompany this condition, restoration of fluid and electrolyte balance is a major factor in ensuring a favorable outcome. Loss of plasma into the bowel wall and lumen of the dilated intestine may require additional replacement with whole blood, plasma, or an albumin equivalent. Optimal preparation often necessitates a delay of several hours but is a major determining factor in the success of any surgical procedure done during the neonatal period.

The preoperative use of antibiotics has been recommended in infants with intestinal obstruction to achieve therapeutic blood levels of drug before the time of incision and possible contamination.<sup>104,148</sup> Perforation, fecal spillage, and peritonitis occur so early in the course of neonatal appendicitis that almost all infants with this condition require treatment before surgery. After the diagnosis of gangrenous or perforated appendicitis has been established and surgery has been performed, parenteral antibiotic therapy should be continued for a minimum of 10 days. The combination of clindamycin (or metronidazole), gentamicin (or extended-spectrum cephalosporins), and ampicillin provides adequate coverage against most enteric pathogens and can be used for initial empirical therapy. Alternatively,  $\beta$ -lactam and  $\beta$ -lactamase inhibitor combinations, such as piperacillin and tazobactam or carbapenem antibiotics (e.g., imipenem or meropenem), can be used alone for broad coverage of enteric bacteria, *Pseudomonas* spp., and anaerobic bacteria. Until the infant is able to tolerate alimentation, careful attention to postoperative maintenance of body fluids, electrolyte balance, nutrition, and correction of blood and plasma losses is vital to survival (see "Peritonitis" and "Necrotizing Enterocolitis").

## Peritonitis

Peritonitis in the newborn is most commonly associated with perforation of the gastrointestinal tract, ruptured omphaloceles, or wound infections that follow abdominal surgery.<sup>149</sup> It has been estimated that 20% to 40% of gastrointestinal surgical problems in the neonatal period are complicated by bacterial peritonitis (see "Necrotizing Enterocolitis").<sup>149</sup> At pediatric surgical centers in the United States,<sup>150-152</sup> Great Britain,<sup>153</sup> Hungary,<sup>154</sup> Germany,<sup>155,156</sup> France,<sup>157</sup> and Zimbabwe,<sup>158</sup> 1 to 10 cases per year have been reported in retrospective analyses of peritonitis diagnosed during the first month of life. Among almost 3000 infants admitted to a neonatal intensive care unit (NICU) in Liverpool from 1981 to 1982, there were 6 cases of peritonitis, all from NEC perforation of the gastrointestinal tract.<sup>159</sup> Peritonitis was present in 4 (all of low birth weight) of 501 infants on whom consecutive autopsies were performed from 1960 to 1966 at St. Christopher's Hospital for Children in Philadelphia. These cases represented approximately 3% of all patients with inflammatory lesions associated with death in this age group.<sup>160</sup> Potter<sup>12</sup> considered the peritoneum "one of the most frequent points of localization" in infants dying with sepsis.

A preponderance of boys (2.5:1<sup>158,159</sup>) and a high incidence of prematurity (33%)<sup>152-155</sup> have been found in unselected series of infants with this condition. These features are probably less a characteristic of bacterial peritonitis in the newborn than of the primary surgical and septic conditions that are responsible for its occurrence (particularly NEC). There seems to be a female preponderance among newborns with primary peritonitis.<sup>153</sup> A high incidence of congenital anomalies not involving the intestinal tract has also been observed among neonates with peritonitis.<sup>152,155,161</sup>

## MICROBIOLOGY

The condition that permits bacteria to colonize the peritoneal surface determines the nature of the infecting organisms. Most infants in whom rupture of a viscus and fecal spillage have caused peritonitis are infected by bacteria considered to be part of the normal enteric microflora; however, prior use of antimicrobial agents and colonization patterns within a nursery are important factors in determining which organisms predominate. Although a mixed flora of two to five species can often be recovered,<sup>161</sup> single isolates have been reported in a third of infants with peritonitis.<sup>162</sup> The predominant aerobic organisms usually include *E. coli*, *Klebsiella* spp., *Enterobacter* spp., *Pseudomonas* spp., *Proteus* spp., coagulase-negative and coagulase-positive staphylococci, ungrouped streptococci, *Enterococcus*, and *Candida*.<sup>152,158,162</sup>

Techniques adequate for the isolation of anaerobic organisms have been used infrequently. In a series of 43 consecutive infants with gastrointestinal perforation and bacterial growth from peritoneal fluid, a mixed aerobic-anaerobic flora was isolated, with *Bacteroides* spp. as the predominant anaerobes<sup>161</sup>; remaining specimens grew aerobic or facultative organisms alone, and no culture yielded only anaerobes. In that series and others, the same organisms were frequently isolated from the peritoneal cavity and blood.<sup>150,161</sup>

In contrast to fecal flora isolated from infants with gastrointestinal perforation, gram-positive organisms predominated among neonates with "idiopathic primary



peritonitis.” This condition is caused by sepsis in most cases, but it also has often been associated with omphalitis. Specific organisms in one representative series included *Streptococcus pneumoniae* (three cases); ungrouped  $\beta$ -hemolytic streptococcus (three cases); and *S. aureus*, *Pseudomonas* spp., and *E. coli* (one case each).<sup>152</sup> Gram-positive cocci were also the major isolates in other reports of peritonitis associated with hematogenous dissemination of organisms or extension from a peripheral suppurative focus.<sup>55,162-164</sup>

Rarely, peritonitis may be caused by *Candida albicans* in pure culture or mixed with gram-negative enteric organisms.<sup>165</sup> Because clinical findings in this condition are not different from the findings of bacterial peritonitis, the diagnosis is usually established by blood or peritoneal fluid culture. Severe hypothermia has been described as a possible predisposing cause of bowel perforation and peritonitis caused by *Candida*.<sup>166</sup> In addition to well-recognized risk factors, such as prematurity, antibiotic therapy, and parenteral nutrition with deep venous catheters, NEC may be a significant risk factor for systemic candidiasis, in which it was observed in 37% of 30 infants.<sup>167</sup> Only a single infant in this series had a positive culture for *Candida* spp. from the peritoneum, however. Peritoneal catheters or peritoneal dialysis may also be a risk for direct inoculation of *Candida* organisms into the peritoneal space, which occurred in 1 of 26 children<sup>168</sup> (see Chapter 33).

## PATHOGENESIS

Acute bacterial peritonitis may occur whenever bacteria gain access to the peritoneal cavity, through intestinal perforation, by extension from a suppurative focus, or by the hematogenous route. Cases of “fetal peritonitis” described in earlier reports were actually examples of meconium peritonitis caused by intrauterine intestinal perforation.<sup>169</sup> Although bacterial colonization of the gastrointestinal tract in the first days of life may lead to infection in this condition, it is an aseptic peritonitis in its initial stages. A similar condition with focal perforation of the ileum or colon occurring postnatally has been described in infants with very low birth weight. Blue-black discoloration of the abdomen, caused by meconium staining of the tissues of the underlying skin, may be the first physical finding in these infants. Clinical, radiographic, and histopathologic evidence of infection or inflammation was notably absent in most cases.

Conditions that predispose to neonatal peritonitis are outlined in Box 10-1. Among almost 400 newborns with peritonitis studied from 1959 to 1978, perforation of the intestinal tract was responsible for 72% of cases, with ruptured omphaloceles or gastroschisis responsible for 12%, hematogenous dissemination or “primary” peritonitis responsible for 12%, and omphalitis and postoperative complications responsible for 2% each.<sup>149,155,170</sup> In a comprehensive review of neonatal peritonitis, Bell<sup>149,161</sup> described common sites and causes of gastrointestinal perforation and their relative frequencies (Figs. 10-1 and 10-2).

## CLINICAL MANIFESTATIONS

Neonatal peritonitis is a disease primarily of the first 10 days of life; numerous infants have evidence of peritoneal infection within the first 24 hours.<sup>150,152,158</sup> An analysis of etiologic factors responsible for peritonitis in the newborn

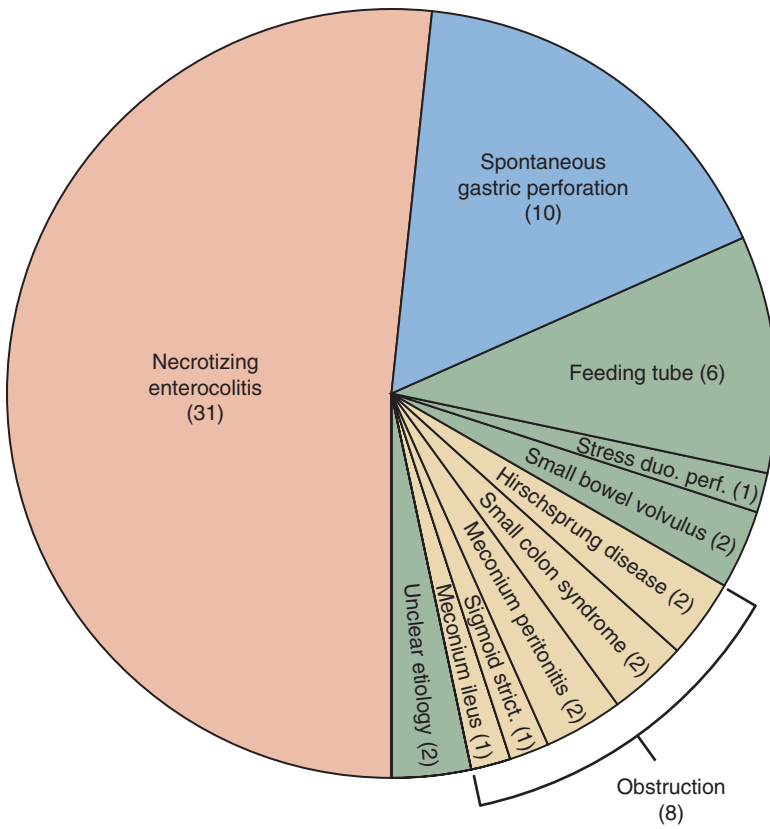
### Box 10-1 Etiology of Bacterial Peritonitis in the Neonatal Period

- Gastrointestinal perforation
- Necrotizing enterocolitis
- Ischemic necrosis
- Spontaneous focal gastrointestinal perforation
- Volvulus
- Hirschsprung disease
- Meconium ileus (cystic fibrosis)
- Postoperative complications
- Congenital anomalies
- Internal hernia
- Catheter-associated vascular thrombosis
- Indomethacin therapy (enteral or parenteral)
- Trauma
  - Feeding tubes
  - Rectal thermometers, catheters, enema
- Intrauterine exchange transfusion
- Paracentesis of ascites fluid
- Meconium peritonitis with postnatal bacterial contamination
- Peptic ulcer: stomach, duodenum, ectopic gastric mucosa
- Acute suppurative appendicitis
- Infection
  - Shigella* or *Salmonella* enterocolitis
  - Prenatal sepsis: listeriosis, syphilis, tuberculosis
  - Neonatal sepsis
  - Suppurative omphalitis transmural migration (theory)
  - Congenital luetic enteritis with necrosis
- Ruptured omphalocele or gastroschisis
- Postoperative: anastomotic leaks, wound dehiscence, wound contamination

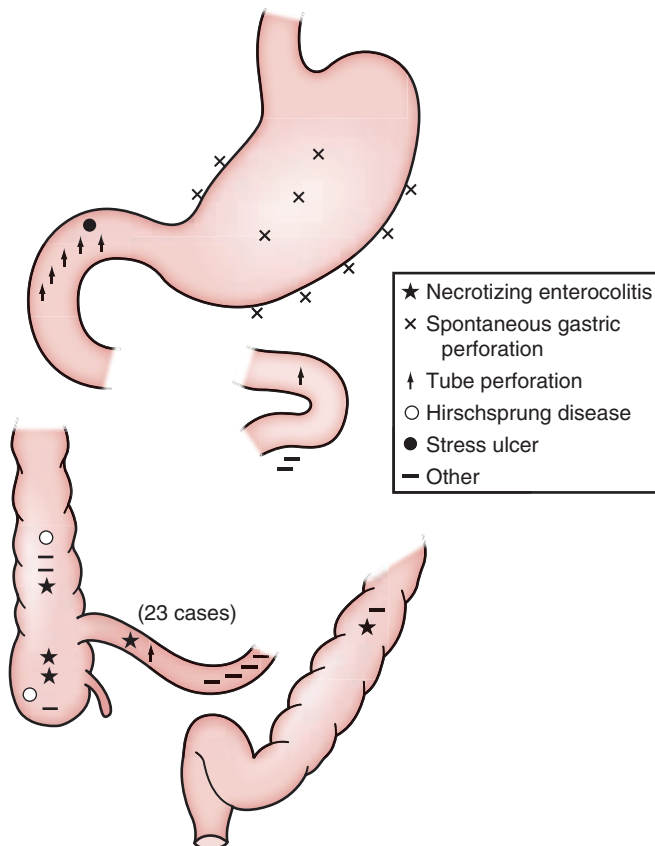
provides a ready explanation for this observation (see Box 10-1). Most cases of NEC<sup>161,171,172</sup> and spontaneous gastric perforation<sup>150,161,170</sup> occur within the first week. Ruptured omphaloceles and gastroschisis often develop early infections, and in infants with congenital obstruction, the onset of alimentation during the first 12 to 24 hours accentuates distention and ischemic necrosis of the bowel wall, which leads to early intestinal perforation. Exchange transfusions are performed most frequently within the first 1 or 2 days of life and may be followed by enterocolitis within 4 to 24 hours in infants in whom perforation ultimately occurs.<sup>107,173</sup> Neonatal sepsis, with potential peritoneal seeding of microorganisms, is more frequent during the first 48 hours of life than during any subsequent period.<sup>174</sup>

The various signs and symptoms present in a young infant with peritonitis were summarized most succinctly by Thelander<sup>175</sup> in 1939:

*“The little patient looks sick. He is cyanotic; the respirations are rapid and grunting; the abdomen is distended, and the abdominal wall, the flanks and the scrotum or vulva are usually edematous. Frequently brawny induration of the edematous area, which may resemble erysipelas, is also present. Food is taken poorly or not at all. Vomiting is frequent and persistent. The vomitus contains bile and may contain blood. The stools are either absent or scant; some mucus or blood may be passed. The temperature may be subnormal, but varying degrees of fever have been reported. The blood count is of little or no value. The hemoglobin content may be very high, which probably indicates only dehydration. The leukocytes may or may not respond with a rise.”*



**Figure 10-1** Causes of perforation in 60 neonates. *duo. perf.*, Duodenal perforation; *strict.*, stricture. (From Bell MJ: Peritonitis in the newborn—current concepts, *Pediatr Clin North Am* 32:1181-1201, 1985.)



**Figure 10-2** Sites of perforation in 60 neonates. (From Bell MJ: Peritonitis in the newborn—current concepts, *Pediatr Clin North Am* 32:1181-1201, 1985.)

**Table 10-2** Signs of Bacterial Peritonitis in the Neonate\*

Sign	Incidence (%)
Abdominal distention	85
Shock	80
Vomiting	70
Constipation	60
Hypothermia	60
Respiratory distress	55
Fever	15
Diarrhea	15

\*Data are based on patients described in references 232, 240, and 243. Redness, edema, and induration of the anterior abdominal wall, noted in only one series, reference 243, are also recognized as characteristic signs.

Although the review by Thelander<sup>175</sup> was limited to neonates with perforation of the intestinal tract, subsequent reports have corroborated the presence of these findings in infants with peritonitis resulting from a wide variety of causes.<sup>151-154,158,161</sup> Not all of the symptoms described may be encountered in any one patient; however, some are always present (Table 10-2).

The large overlap between signs of neonatal peritonitis and sepsis can make it difficult to differentiate the two on the basis of clinical findings. Signs of intestinal obstruction, such as abdominal distention and vomiting, which are seen in 10% to 20% of newborns with sepsis,<sup>9</sup> may reflect a coexistent unrecognized peritonitis. Because the early use of antibiotics often cures hematogenous peritonitis in infants with septicemia, the diagnosis may be missed in infants who survive. Peritonitis unassociated with perforation was found at postmortem examination in 9 of 121 infants with septicemia dying from 1976 to 1988.<sup>149</sup>

## DIAGNOSIS

Ultrasonography<sup>47</sup> or abdominal radiographs taken in the erect and recumbent positions showing free intraperitoneal fluid can be helpful in the diagnosis of peritonitis, and sometimes the only evidence of perforation is apparent on these imaging studies. Absence of definition of the right inferior hepatic margin, increased density of soft tissue, and the presence of “floating” loops of bowel have been recorded as positive signs of ascites.<sup>147</sup> Diagnostic paracentesis can be useful in determining whether the fluid is caused by bacterial peritonitis,<sup>163,176</sup> hemoperitoneum, chylous ascites,<sup>177</sup> or bile peritonitis.<sup>178</sup>

The left lateral (“left-side down”) decubitus film is of great value in showing small amounts of intraperitoneal gas.<sup>161</sup> Although pneumoperitoneum can be caused by mediastinal air dissecting from the chest into the abdomen,<sup>179</sup> free gas in the peritoneal cavity usually indicates intestinal perforation. An associated pneumatosis intestinalis should suggest the diagnosis of NEC but is not specific for this condition. Several patterns of intraperitoneal gas distribution have been described<sup>47,107,180,181</sup>: the air-dome sign, falciform ligament sign, football sign, lucent-liver sign, saddlebag sign, and gas in the scrotum. Absence of a gastric air-fluid level on an erect abdominal radiograph, with a normal or decreased amount of gas in the small and large

bowel, strongly favors a diagnosis of gastric perforation.<sup>180</sup> This finding is almost always accompanied by pneumoperitoneum. In equivocal cases, metrizamide contrast studies of the bowel can be helpful in establishing a diagnosis of intestinal perforation.<sup>182</sup>

Failure to show free air in the peritoneal cavity does not rule out a diagnosis of perforation, particularly if air swallowing has been reduced or prevented through orotracheal intubation, nasogastric suction, or use of neuromuscular blocking agents.<sup>176,182,183</sup> In some cases, the amount of gas in the bowel lumen is so small that even if perforation occurs, the gas could escape detection. Alternatively, small leaks may become walled off and the free air reabsorbed.<sup>182,184,185</sup> In three large series of infants with peritonitis in whom a patent site of perforation was found at surgery, pneumoperitoneum was absent in 35% to 75%.<sup>152,161</sup> Radiographic evidence of intestinal obstruction, although a common cause or consequence of peritonitis, lacks sufficient specificity to be a consistent aid to diagnosis. A diffuse granular appearance of the abdomen, with one or more irregular calcific densities lying within the bowel lumen or in the peritoneal cavity, should suggest a diagnosis of meconium peritonitis with possible bacterial superinfection.<sup>169</sup>

## PROGNOSIS

Prematurity, pulmonary infections, shock, and hemorrhage related to perforation of the intestinal tract, sepsis, and disseminated intravascular coagulopathy are often the factors responsible for the death of neonates, who may concurrently have peritonitis diagnosed at surgery or at postmortem examination. For this reason, case-fatality rates often represent the mortality rate among newborns dying with, rather than because of, infection of the peritoneal cavity.<sup>155,161</sup> Before 1970, the incidence of fatalities was exceedingly high when peritonitis was associated with gastrointestinal perforation; mortality rates of 70% were observed in large series.<sup>152-154,157,158,185</sup> Heightened awareness of conditions associated with perforation, more rapid diagnosis, and improved surgical management led to a doubling of survivors in subsequent years.<sup>155</sup> The cause of perforation seems to influence the likelihood of survival, with spontaneous gastric perforation having the lowest mortality rate (10%) and perforation of the duodenum caused by a feeding tube the highest mortality rate (50%); NEC (40%) and all other causes (25%) occupy intermediate positions.<sup>161</sup>

As survival rates have improved, the number of nonlethal complications after perforation has increased proportionally. In one review, two thirds of surviving infants had significant postoperative complications pertaining to infection (e.g., bacteremia, wound infection, intraabdominal abscess) or gastrointestinal tract dysfunction (e.g., esophageal reflux, obstruction, stomal stenosis).<sup>161</sup> Secondary surgical procedures to correct these problems were required in more than half of the infants. Parenteral hyperalimentation for nutritional support during the recovery period was required in 60% of infants.

The mortality rate among neonates with peritonitis from causes other than perforation of the bowel, such as sepsis,<sup>152,154,158</sup> omphalitis,<sup>158</sup> or a ruptured omphalocele,<sup>152,155,158</sup> although high in the past, has not been



reassessed in many years.<sup>161</sup> Early diagnosis and institution of appropriate surgical therapy are major factors in reducing the mortality rate.<sup>161</sup> Factors with an apparent adverse influence on prognosis include low birth weight<sup>152,153,155,158,161</sup> and congenital malformations.<sup>155</sup>

## TREATMENT

The treatment of bacterial peritonitis is directed primarily toward correction of the causative condition. Careful attention to preoperative preparation of the infant is essential to survival. As soon as bowel obstruction or perforation is diagnosed, continuous nasogastric suction should be instituted for decompression and prevention of aspiration pneumonitis. Diagnostic needle paracentesis is also useful for relief of pneumoperitoneum and may facilitate exchange of gas by reducing the intraabdominal pressure. Shock, dehydration, and electrolyte disturbances should be corrected through parenteral administration of appropriate electrolyte solutions, plasma, or plasma substitutes. If blood is discovered in fluid recovered by gastric suction or abdominal paracentesis, use of whole blood, packed red blood cells, or other fluids may be necessary to correct hypovolemia. Persistent bleeding must be evaluated for disseminated intravascular coagulation or thrombocytopenia, or both, and treated accordingly. Hypothermia, which frequently accompanies neonatal peritonitis, should be corrected before induction of anesthesia. Infants who are unable to tolerate oral or tube feedings within 2 or 3 postoperative days should be started on parenteral hyperalimentation.

If a diagnosis of peritonitis is established at the time of paracentesis or surgery, aerobic and anaerobic cultures of peritoneal contents should be taken before initiation of antibiotic therapy. Parenteral administration of a combination of gentamicin or an extended-spectrum cephalosporin and clindamycin and ampicillin should be continued for 7 to 10 days.<sup>141,148</sup> Other antibiotics that provide a broad spectrum against enteric organisms, *Pseudomonas* spp., enterococci, and anaerobic organisms include  $\beta$ -lactam and  $\beta$ -lactamase inhibitor compounds and carbapenems. In the event of a poor clinical response, culture and susceptibility studies of the infecting organisms should be used as guides for modifying therapy.

Leakage of intestinal contents sometimes results in formation of a localized abscess, rather than contamination of the entire peritoneal cavity. Management of infants with such an abscess should include antimicrobial therapy and surgical drainage of the abscess by the most convenient route.

## Necrotizing Enterocolitis

Necrotizing enterocolitis with necrosis of the bowel wall is a severe disease that is one of the most common and devastating infections of the NICU.<sup>186-191</sup> The risk of NEC is inversely related to gestational age, with prematurity and low birth weight the most important risk factors. NEC may develop in approximately 5% of newborns born earlier than 32 weeks of gestation and 10% of infants born earlier than 28 weeks of gestation<sup>192</sup>; for infants between 500 and 1500 g birth weight born between 2000 and 2009, the incidence of NEC ranged from 4.6% to 6.1%.<sup>193</sup> Less than 10% of NEC cases

occur in term infants; in these cases, the disease developed in those already admitted to a NICU for some other reason and thus as a complication of treatment, not as a primary diagnosis.<sup>194,195</sup> The overall mortality rate for NEC exceeds 20% and is significantly higher in those infants requiring surgical interventions.<sup>196</sup> The financial cost of caring for infants with NEC in the United States alone may approach \$1 billion.<sup>186</sup>

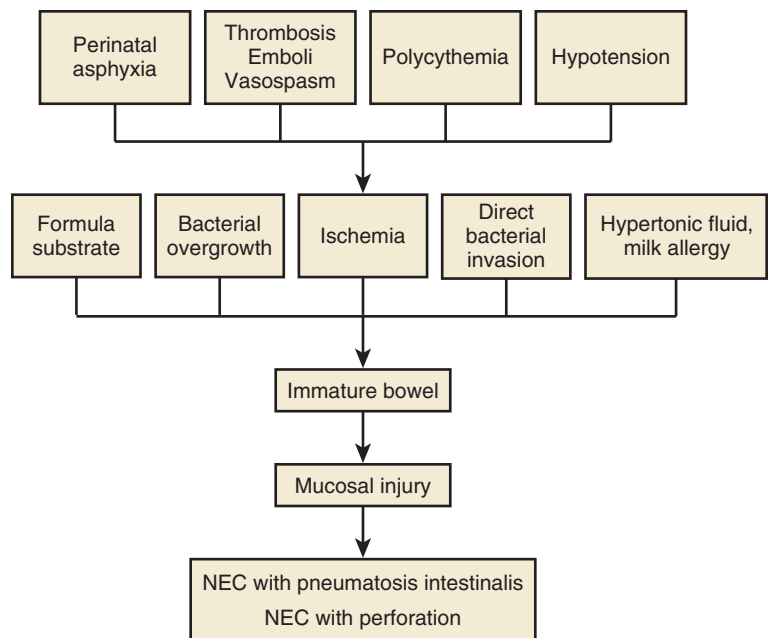
## PATHOLOGY AND PATHOGENESIS

Bowel wall necrosis of variable length and depth is the characteristic feature of NEC, with perforation in one third of affected infants generally in the terminal ileum or cecum, where microcirculation is poor. The pathogenesis of NEC is not definitively established, but the etiology is de facto multifactorial with a confluence of predisposing factors contributed by intestinal immaturity, ischemia, infection, and inflammatory response. The preterm infant possesses an immature gastrointestinal tract supplied by a precarious vasculature prone to imbalances in vascular tone. An additional stress, or multiple additional stresses, may trigger the cascade of events that leads to the pathognomonic findings of NEC: disruption of the mucosal barrier, bacterial invasion and proliferation, and gas formation within the bowel wall (Fig. 10-3). Potential triggers may include the increased intestinal metabolic demand of enteral feeding, disturbance in the normal ecologic balance of the gut microflora, and the exaggerated inflammatory response of the highly immunoreactive neonatal intestinal mucosa.<sup>186,191,197</sup> Surgical specimens from early stages of the disease show mucosal edema, hemorrhage, and superficial ulceration with very little inflammation or cellular response. By the second or third day, after progression to pneumatosis and transmural necrosis of the bowel wall, bacterial proliferation and the acute inflammatory reaction become more prominent.<sup>198</sup>

Limited data available from twin studies or candidate gene association studies (e.g., cytokine genes) have yet to establish any specific genetic risk factors for development of NEC.<sup>199,200</sup> Maternal complications of pregnancy, labor, and delivery and neonatal respiratory distress syndrome are thought to be unrelated to the development of NEC, whereas evidence linking NEC to birth asphyxia, hypotension, hypothermia, use of vascular catheters, exchange transfusion, feeding history, abnormalities of gut motility, neonatal achlorhydria, and the presence of patent ductus arteriosus is often contradictory. Each of these conditions, singly or together, may act as a stress leading to mucosal injury, but none has been consistently associated with NEC. NEC has occurred among apparently healthy infants with no known predisposing risk factors.<sup>194</sup>

A number of studies suggest that the incidence of NEC could be higher in NICUs in which enteral feedings are introduced early or in which increased feeding volumes are pushed aggressively<sup>201,202</sup>; however, no absolute consensus has emerged on the ideal protocol for feeding advancement with respect to risk of NEC, especially in very-low-birth-weight infants, where delayed weight gain itself is associated with counterbalancing medical risks.<sup>203</sup>

Infants fed maternal milk have a lower risk of NEC, but the absolute level of protection can be difficult to quantify



**Figure 10-3** Pathogenesis of mucosal injury leading to necrotizing enterocolitis (NEC). (Modified from Walsh MC, Kliegman RM: Necrotizing enterocolitis. *Pediatr Basics* 40:5, 1985.)

because independent risk factors for NEC may also reduce the likelihood of receiving breast milk. However, a recent study indicated that a diet exclusively based on human milk was associated with a lower rate of NEC than a mixed diet of human milk and bovine milk-based products.<sup>204</sup> A recent meta-analysis of clinical trials of formula versus donor breast-milk feeding identified a lower risk of NEC in the human milk-fed infants.<sup>205</sup> In a neonatal rat model of NEC, maternal milk was protective compared with artificial formulas; similar to human NEC, artificial feeding of maternal milk reduced the incidence and severity of NEC injury, and interleukin-10 expression was significantly increased when neonates were fed maternal milk.<sup>206</sup>

## MICROBIOLOGY

A long-standing hypothesis postulates that aberrant intestinal microbial colonization in preterm infants is an important contributing factor to the development of NEC.<sup>207,208</sup> Potential microbial etiologies of NEC have been pursued for decades, based on circumstantial evidence including common findings of bacteremia and/or endotoxemia in affected infants and the concept that the pathognomonic imaging finding of pneumatosis intestinalis is suggestive of a gas-forming organism proliferating in submucosal bowel tissue.<sup>186</sup>

The analogous pathology of necrotizing enteritis caused by *Clostridium septicum* and *Clostridium perfringens* in domestic animals, older children, and adults favored suggestions that *Clostridium* spp. (e.g., *C. perfringens*, *C. difficile*, *C. butyricum*) might act as a primary pathogen in NEC.<sup>209,210</sup> Subsequent studies have indicated, however, that these species can often be acquired from the nursery environment and could frequently be recovered from healthy neonates.<sup>211,212</sup> Clostridial cytotoxin, which had been recovered from the stool of infants involved in an outbreak of NEC,<sup>213</sup> has also been found in the stool of 90% of normal infants.<sup>211,212</sup> The role of *Clostridium* spp. in NEC thus remains unclear.

The  $\delta$ -toxins, hemolysins of coagulase-negative staphylococci and *S. aureus*, have also been proposed as possible primary toxins capable of producing NEC in infants. Frequent colonization by  $\delta$ -toxin staphylococci and higher levels of toxin production by associated strains causing NEC and one outbreak with  $\delta$ -toxin-producing *S. aureus* strains have been reported.<sup>214,215</sup> Prospective studies have documented significant shifts in aerobic bacterial bowel flora within 72 hours before onset of clinical NEC<sup>216</sup>; the observed shift results from preclinical changes in the intestinal environment. This shift suggests that bacteria isolated at the time of onset were present because of possible intraluminal changes and are not directly involved in NEC. Pending further experimental or epidemiologic observations, the weight of evidence indicates that although bacteria or bacterial toxins may play a primary or secondary role in the pathogenesis of NEC, the occasional association of this condition with a single organism probably reflects patterns of intestinal colonization prevalent in the nursery at the time of an outbreak. Despite intensive efforts to identify a specific infectious agent or toxin in the cause of NEC, convincing reports implicating the same pathogen in more than one outbreak have not appeared.

The advent of 16S ribosomal RNA technology and high-throughput methods for metagenomic analysis should facilitate comprehensive studies of the gut microbes of very-low-birth-weight infants and their disease associations.<sup>208</sup> Smaller preliminary studies using such molecular methods suggest that NEC may be associated with the presence of unusual intestinal microbial species and an overall reduction in the diversity of microbiota; the latter finding may reduce resistance to pathogen colonization, a normal function of the healthy intestinal microbiome.<sup>186</sup>

## CLINICAL MANIFESTATIONS

Signs of NEC usually develop in the first 7 days of life, and 50% or greater of cases are recognized within 5 days of

**Table 10-3** Modified Bell Staging Criteria and Recommendations for Therapy for Necrotizing Enterocolitis

Stage	Systemic Signs	Intestinal Signs	Radiologic Findings	Treatment
IA (suspected)	Temperature instability Apnea and bradycardia Lethargy	Elevated residuals Mild abdominal distension Emesis Guaiac plus stools	Normal Mild ileus	NPO Antibiotics × 3 days
1B (suspected)	Same as IA	Frank rectal blood	Same as IA	Same as IA
IIA (definite), mild	Same as IA and IB	Same as IB, plus absent bowel sounds ± Abdominal tenderness	Dilation Ileus Pneumatosis intestinalis	NPO; Antibiotics for 7-14 days if examination normal in 24-48 hr
IIB (definite), moderate	Same as IIA with Mild metabolic acidosis Mild thrombocytopenia	Same as IIA with definite abdominal tenderness ± abdominal cellulitis or right lower quadrant mass	Same as IIA with Portal gas ± ascites	NPO Antibiotics × 14 days
IIIA (advanced), bowel intact	Same as IIB plus Hypotension Bradycardia Severe apnea Respiratory/metabolic acidosis Disseminated intravascular coagulation Neutropenia	Same as IIB plus Peritonitis Marked tenderness Abdominal distension	Same as IIB with ascites	Same as IIB plus 200 mL/kg fluid Inotropic agents Assisted ventilation Paracentesis
IIIB (advanced), bowel perforated	Same as IIIA	Same as IIIA	Same as IIIA plus pneumoperitoneum	Same as IIIA plus surgery; NPO

Modified from Walsh MC, Kliegman RM: Necrotizing enterocolitis: treatment based on staging criteria, *Pediatr Clin North Am* 33:179-201, 1986. NPO, Nothing by mouth.

birth.<sup>171,172</sup> Small immature newborns often develop illness later, during the second to eighth week, whereas low-risk term infants may become ill shortly after delivery, as early as the first 24 hours.

NEC is a disease with a wide spectrum of manifestations, ranging from a mild gastrointestinal disturbance to a fulminant course characterized by early bowel perforation, peritonitis, sepsis, and shock.<sup>217,218</sup> A staging system (Table 10-3) taking these clinical variations into account may be useful in guiding patient evaluation and therapy.<sup>219</sup> The apparent stage of disease for an individual infant usually can be defined on the second day of illness. An infant who exhibits only mild systemic and intestinal signs 24 to 48 hours after onset is unlikely to develop a more serious illness.<sup>220</sup>

The classic presentation of NEC includes a triad of abdominal distention, retention of gastric contents, and gastrointestinal bleeding.<sup>186,197,219,220</sup> These findings are often preceded or accompanied by signs consistent with sepsis, such as lethargy, poor feeding, temperature instability, apnea, and bradycardia; diarrhea is a variable finding. Progression of bowel wall necrosis leading to perforation, peritonitis, and sepsis is reflected in deteriorating vital signs, accompanied by persistent acidosis, clotting disorders, and circulatory collapse. Redness, induration, and edema of the anterior abdominal wall are commonly described in the advanced stages of NEC. In the absence of aggressive medical and surgical intervention, the course is rapidly downhill when late signs appear.

## DIAGNOSIS

Radiographic signs of NEC are largely nonspecific,<sup>221</sup> and interobserver variability in the interpretation of films is

substantial.<sup>222,223</sup> Radiographic examination of the abdomen remains the most reliable aid, however, in establishing a diagnosis of NEC. Ileus with generalized bowel dilatation and abdominal distention are the earliest radiologic findings.<sup>221</sup> Increasing distention, separation of loops by peritoneal fluid or edema of the bowel wall, a gasless abdomen, pneumatosis intestinalis, and hepatic or portal air occur as NEC worsens.<sup>221</sup> A persistent single dilated loop of bowel remaining relatively unchanged in shape and position in serial films is strongly suggestive,<sup>224</sup> but not diagnostic, of localized bowel ischemia with impending perforation.<sup>225</sup>

If free air or ascites is absent on initial abdominal examination, supine and left lateral decubitus films should be obtained every 6 to 8 hours until improvement or definitive surgery or invasive diagnostic measures have ruled out the presence of perforation. When perforation occurs, it is usually within 1 day after diagnosis<sup>226</sup> but may be delayed for 5 or 6 days.<sup>227,228</sup> Although the presence of pneumoperitoneum or intraperitoneal fluid generally indicates perforation, its absence does not exclude perforation. In one study,<sup>226</sup> only 63% of infants with NEC and proven perforation had free air, 21% had ascites, and 16% had neither free air nor ascites.

When plain films are normal or equivocal, other studies may be diagnostic. A metrizamide gastrointestinal series may show intestinal perforation or abnormalities of the bowel wall, mucosa, or lumen.<sup>229</sup> Real-time ultrasonography may reveal portal venous and hepatic parenchymal gas in standard radiographs.<sup>230,231</sup> Changes on abdominal magnetic resonance imaging may offer a potential for diagnosis early in the course of NEC.<sup>232</sup>

A rapid and direct means of establishing the presence of intestinal necrosis or perforation is by abdominal



paracentesis.<sup>233</sup> This procedure is unnecessary in infants to rule out NEC or in infants improving on medical therapy. The procedure is generally reserved for infants suspected, on the basis of clinical, radiographic, and laboratory findings, to have intestinal gangrene. Paracentesis has an accuracy of greater than 90% in determining the need for an operation in NEC.<sup>233</sup> False-positive results are rare; false-negative results are quite common. Patients with a dry tap should be closely observed under medical therapy with continuing serial paracenteses until indications for or against surgical intervention are clearly defined. Infants with a positive result should undergo exploratory surgery immediately.

Thrombocytopenia and disseminated intravascular coagulation are the most common hematologic complications,<sup>234,235</sup> particularly in the presence of bowel gangrene or perforation. Platelet-activating factor has been used to assist in the staging of NEC<sup>236</sup>; a cutoff level of 10.2 ng/mL had a positive predictive value of 100% in identifying infants with stage II or III NEC. Leukopenia and absolute granulocytopenia, apparently caused by margination of white blood cells rather than bone marrow depletion,<sup>237</sup> also have occurred during early stages of the illness.<sup>234,235</sup> A low absolute granulocyte count persisting for 2 to 3 days is associated with a poor prognosis. No consistent urinary abnormalities have been described for NEC, although increased lactate excretion, reflecting heightened enteric bacterial activity, may occur.<sup>238</sup> Increased amounts of fecal-reducing substances have been found in almost three fourths of formula-fed premature infants during early stages of NEC, before the onset of abdominal distention, poor feeding, or emesis.<sup>239</sup>

The evaluation of patients with NEC should include culture of blood and, when appropriate and clinically safe, cerebrospinal fluid, urine, and stool. The likelihood of bacteremia accompanying NEC depends on the severity of bowel involvement; the reported incidence has ranged from 10% to 67% among symptomatic infants. Combined data from several large studies showed positive blood cultures in about one third of newborns with NEC.<sup>227,228, 240</sup> The usual organisms have been *E. coli*, *Klebsiella* spp., *S. aureus*, and *Pseudomonas* spp., whereas enterococci and anaerobic bacteria were isolated occasionally. A spectrum of organisms similar to those causing neonatal sepsis has been isolated from the peritoneal fluid. Meningitis may accompany bacteremia, occurring in approximately 1% of NEC cases.<sup>241</sup>

## TREATMENT

Early and aggressive treatment must be initiated for any infant suspected to have NEC. The modified Bell staging system of NEC may guide diagnostic studies, management, antibiotics, and surgical consultation and intervention (see Table 10-3). Umbilical catheters should be removed whenever possible, oral feedings should be stopped, and nasogastric tube drainage should be instituted. Fluid and electrolyte deficits and maintenance require rigorous attention; blood, plasma, or colloid infusions are often necessary for volume expansion and maintenance of tissue perfusion.

After appropriate cultures are obtained, broad-spectrum parenteral antibiotic therapy should be started.<sup>242</sup> Historically, antibiotic coverage has consisted of ampicillin,

gentamicin, and either clindamycin or metronidazole. More recently, initial therapy with meropenam or  $\beta$ -lactam and  $\beta$ -lactamase inhibitor combinations (e.g., piperacillin plus tazobactam) with gentamicin may provide coverage against anaerobic, gram-negative enteric aerobic, and many gram-positive pathogens. Vancomycin may be required for resistant gram-positive species, including MRSA. Gentamicin and vancomycin dosages should be modified as necessary on the basis of serum levels. The need for inclusion of clindamycin to provide activity against anaerobic bacteria in the management of NEC has been questioned,<sup>243</sup> based on the observation that anaerobic bacteria are late bowel colonizers, present in relatively much lower numbers in infants than in adult subjects, and that anaerobes other than *Clostridium* spp. have been infrequently identified in NEC.

After immediate treatment has been started, follow-up studies should be instituted. These include serial examinations with measurement of abdominal girth; testing of stools for blood; levels of serum electrolytes, blood glucose, and arterial blood gases; complete blood cell count and platelet count; urine-specific gravity; and supine and left lateral decubitus abdominal radiographs. These tests should be considered every 6 to 8 hours until the infant's clinical condition stabilizes. Attention to vital functions should be provided as necessary on the basis of clinical, laboratory, or radiographic studies. Parenteral nutritional support through a central or peripheral vein must be started as soon as possible.

Early recognition and prompt initiation of medical therapy may reduce the need for surgery. Generally accepted criteria for surgical exploration are a deteriorating clinical condition despite appropriate medical therapy, signs of peritonitis, presence of free air within the abdomen, or a positive paracentesis result. The principles of surgical preparation and management have been discussed by several investigators.<sup>244-246</sup> In addition to laparotomy with removal of necrotic bowel, closed peritoneal drainage has been proposed as an alternative in very small infants, with a resultant survival of greater than 50%.<sup>247</sup>

## PREVENTION

Initial observations implicating bacterial proliferation as a factor in pathogenesis of NEC prompted efforts at suppression of gut flora with topical antibiotics in the hope of preventing NEC. Attempts to prevent NEC by giving oral kanamycin or gentamicin prophylactically generated contradictory data. In controlled clinical trials, a significant reduction in the incidence of NEC in treated premature infants was shown in some trials,<sup>248,249</sup> whereas in others, investigators were unable to show any protective effect.<sup>250</sup> Previous studies revealed selective growth of resistant organisms in bowel flora<sup>251</sup> and evidence of significant systemic absorption of aminoglycoside antibiotics in neonates,<sup>252</sup> suggesting that oral aminoglycoside prophylaxis is not free of potential risks. Potential risk factors have not been examined in vancomycin trials, however. Until additional evidence is presented indicating clear-cut benefits from the use of oral aminoglycosides or vancomycin, it does not seem that either agent should be used routinely for prevention of NEC in premature infants.

A number of recent studies have indicated that oral probiotics may alter the bowel flora of the very-low-birth-weight infant to reduce the incidence and severity of NEC.<sup>253,254</sup> Lin and colleagues<sup>255</sup> determined the incidence of NEC (stage II or greater) was significantly lower in the probiotic treatment group (2 of 180) when compared with the control group (10 of 187). Bin-Nun and colleagues<sup>256</sup> reported a reduction in the incidence of NEC with probiotic supplementation from 16% to 4%, with a further reduction in severity of disease among affected infants by Bell's criteria. A meta-analysis of 11 trials of probiotics concluded that the risk for NEC and death was significantly lower, but the risk for sepsis did not differ significantly from those neonates not receiving probiotics.<sup>257</sup>

Excessive or accelerated feedings have been associated with increased frequency of endemic NEC,<sup>258</sup> and some clinicians have recommended a schedule of slow advancement of daily feeding volumes limited to about 20 mL/kg/day. Infants with NEC are more likely to have been fed earlier, to have received full-strength formulas sooner, and to have received larger feeding volumes and increments, and stress and associated respiratory problems may make such infants more vulnerable to NEC.<sup>259</sup> The duration of feeding and rate of advancement of feed volumes may be modifiable risk factors for NEC in preterm infants.<sup>202,203</sup>

Carrion and Egan<sup>260</sup> suggested that relative hypochlorhydria of the neonate may contribute to NEC and found that hydrochloric acid supplements (0.01-0.02 mL of a 1.0-N solution of HCl per mL of formula) significantly reduced NEC rates and lowered gastric pH. Another study has showed that standardized feedings begun at a median of 4 days after onset of NEC can be associated with an abbreviated time until institution of full enteral feedings, a reduced incidence of the use of central catheters and catheter infections, and, ultimately, a shorter hospital stay.<sup>261</sup> Reports of prevention of necrotizing enterocolitis in low-birth-weight infants by IgA-IgG feeding<sup>262,263</sup> are likely functionally correlated to the benefits of breast milk in reducing incidence of the syndrome.<sup>204</sup>

## PROGNOSIS

The mortality rate of NEC is difficult to determine because mild cases of suspected NEC are probably more common than is recognized.<sup>264</sup> In studies in which analysis has been limited to infants with "definite NEC," mortality figures range from 20% to 40%,<sup>196</sup> and a longitudinal study over 25 years.<sup>265</sup> A poor prognosis has been linked with very low birth weight, associated congenital defects, bacterial sepsis, disseminated intravascular coagulation, intestinal perforation, and persistent hemodynamic or respiratory instability.<sup>227,266</sup> Surgical intervention, generally reserved for the sickest infants with more extensive bowel involvement, is also associated with higher mortality rates.<sup>196,265</sup>

Infants who survive the acute phase of illness generally do well, although NEC may recur in 5% to 10%.<sup>265,267</sup> In addition to surgical complications (e.g., short bowel syndrome, anastomotic leaks, fistula formation), enteric strictures are probably the most common delayed complication in surviving infants, occurring in 4% to 20%. Usually found at sites of ischemia and necrosis in terminal ileum or colon,<sup>268</sup> these strictures often become apparent within a few weeks but may be delayed 18 months. When multiple strictures

occur, the intervening normal bowel may form an enterocyst.<sup>269</sup> Clinically, strictures manifest as frequent episodes of abdominal distention, often with vomiting, obstipation, or hematochezia. Diagnosis is confirmed by gastrointestinal contrast studies. Surgery with removal of the stenotic site is necessary to achieve a cure. The need for bowel resection is one of the most common severe complications of NEC and the major cause of the short bowel syndrome in pediatric patients.

Long-term follow-up of low-birth-weight infants with severe NEC (i.e., Bell stages II and III) has documented higher rates of subnormal body weight (15%-39%) and head circumference (30%) in addition to significant neurodevelopmental impairment (83%).<sup>270</sup> Premature infants with NEC have longer NICU stays, acquire more nosocomial infections, have lower nutrient intake, grow slower, and have higher rates of retinopathy of prematurity and bronchopulmonary dysplasia than age-matched controls.<sup>271</sup> A synergistic effect of NEC and invasive infection can predispose to more severe neurodevelopmental outcomes, including cerebral palsy.<sup>272</sup>

## Endocarditis

Neonatal bacterial endocarditis, previously uncommon, has been recognized more frequently in recent years. About 60 cases that meet clinical and bacteriologic criteria sufficient to establish this diagnosis were reported in the literature before the mid-1980s.<sup>35,273-279</sup> The prolonged survival of critically ill infants, including infants with complex congenital heart disease, and the increased use of intravascular catheters, together with advances in the diagnostic sensitivity and availability of echocardiography, may be responsible for an increased recognition of endocarditis. In a 35-year review of 76 cases of endocarditis in children, 10% of patients were younger than 1 year; the youngest patient was 1 month old.<sup>280</sup> Of patients, 62 (83%) had congenital heart disease, and 77% had had prior surgery. Central venous catheters were additional significant risk factors.

At the Mercy Hospital for Women in Melbourne, of more than 12,000 infants admitted to the special care nursery, 8 infants with endocarditis were identified; gestation less than 32 weeks, birth weight less than 1500 g, thrombocytopenia and neutropenia, or increased neutrophil count were common features. The tricuspid valve (8 cases) and mitral valve (2 cases) were most frequently involved. *S. aureus* was isolated from 3 infants and coagulase-negative *Staphylococcus*, *Bacteroides fragilis*, *E. faecalis*, and *E. coli* were isolated 1 each among the infants.<sup>281</sup> In a NICU in Manchester, United Kingdom, between 1990 and 1992, 12 cases of ultrasound-proven endocarditis in newborn infants with structurally normal hearts were identified<sup>282</sup>; two thirds were premature, low-birth-weight infants, whereas the other one third had surgical problems with indwelling central catheters. Among these patients, 10 had coagulase-negative staphylococci identified from blood cultures, 1 had *Streptococcus sanguinis*, and 1 had *C. albicans*.

Etiologic agents of bacterial endocarditis in newborns, which have been identified by isolation from blood cultures or morphologic characteristics of organisms entrapped within valvular vegetations examined at autopsy, include

most commonly *S. aureus*, coagulase-negative staphylococci, viridans streptococci, and group B streptococci; less common agents that have been reported include *P. aeruginosa*, *Serratia marcescens*, *Streptococcus pneumoniae*, *Neisseria gonorrhoeae*, *K. pneumoniae*, and *Proteus mirabilis*. Despite widespread cardiovascular involvement associated with congenital syphilis, there is no conclusive evidence that this disease produces valvular heart lesions in infected infants.

Factors that predispose a newborn to endocarditis are not well understood, although intravascular catheters are associated with endocarditis. In contrast to older children, in whom congenital heart disease is often associated with endocarditis,<sup>283</sup> cardiac anomalies are more unusual in neonatal infection.<sup>275,277,282</sup> Bacteremias arising from an infected umbilical stump<sup>273</sup> or skin lesions<sup>284</sup> are presumed sources of valvular involvement in other infants; the invasive organisms associated with these conditions and with neonatal endocarditis in general can infect normal heart valves.<sup>285</sup> Nevertheless, the greater frequency of bacterial and fungal endocarditis in newborns in recent years, particularly in association with prematurity or placement of central vessel catheters, or both, indicates that other, more complex mechanisms may also be operative in some cases.

Damage to the intracardiac endothelium with formation of a sterile platelet-fibrin thrombus at the site of the injury are often the initiating events in a patient with endocarditis. Endocardial trauma caused by placement of cardiac catheters, disseminated intravascular coagulation, and various nonspecific stresses associated with prematurity, such as hypotension and hypoxia, has been implicated in the genesis of thrombi.<sup>285-288</sup> Nonbacterial thrombotic endocarditis or verrucous endocarditis usually remains uninfected and is described as an incidental finding at autopsy.<sup>288</sup> With bacteremia, implantation of organisms may lead to valvular infection. Whether this mechanism or direct bacterial invasion is primarily responsible for valvulitis is unknown. A similar pathogenesis has been postulated for formation of mycotic aortic aneurysms in newborns.<sup>289</sup>

Endocarditis should be suspected in any neonate, particularly a premature infant, with an indwelling vascular catheter, evidence of sepsis, and new or changing heart murmurs. When these findings are accompanied by persistent bacteremia, or by signs of congestive heart failure without underlying heart disease, the diagnosis must be considered seriously. Although Janeway lesions, a generalized petechial rash, and splinter hemorrhages have been seen, murmurs characteristic of semilunar valve insufficiency, Osler nodes, Roth spots, arthritis, and other findings typical of valvular infection in adults and older children have not been observed in neonates. Multiple septic emboli with involvement of the skin, bones, viscera, and central nervous system are common findings, however.<sup>277-279,283,285,287</sup>

Two-dimensional echocardiography stands as an invaluable rapid, noninvasive method for diagnosing endocarditis.<sup>276-278</sup> Although it cannot differentiate between infected and sterile vegetations and other valvular lesions (discussed later), imaging is quite specific, and false-positive readings are uncommon. Less certainty can be placed on a negative report. Despite detection of vegetations 2 mm in diameter with echocardiography, the number of false-negative examinations is significant.<sup>278,290</sup> A diagnosis of bacterial endocarditis should be considered in any infant with a

compatible history and physical findings regardless of the results obtained by echocardiography. Use of transesophageal echocardiography, which provides detailed views of the mitral and tricuspid valves, and application of color flow Doppler imaging, which can identify areas of turbulence as blood passes over vegetations or through narrowed valve leaflets, improves diagnostic accuracy.<sup>291</sup>

When endocarditis is suspected, specimens of blood, cerebrospinal fluid, and urine obtained by catheterization or suprapubic aspiration should be sent for bacterial and fungal culture. Because blood drawn from a central catheter often contains organisms colonizing the line but not present in the systemic circulation, at least two peripheral venous blood cultures should be obtained before antimicrobial therapy is initiated. Volumes of 1 to 5 mL, depending on the infant's size, should be adequate. Routine laboratory studies are helpful in supporting a diagnosis of endocarditis in the newborn. The leukocyte count, differential count, and platelet count are usually indicative of sepsis, rather than cardiac valve infection in particular. Microhematuria has been reported, although rarely. A chest radiograph should be obtained to determine signs of cardiac failure or pulmonary or pleural space infection. CT or MRI of the brain can be helpful in an infant with neurologic signs, particularly if left-sided endocarditis or a right-to-left shunt exists. Baseline determinations of inflammatory markers are useful and can be used for assessing the efficacy of the therapy; erythrocyte sedimentation rate and C-reactive protein level have been used.

Intravenous therapy with a penicillinase-resistant penicillin and an aminoglycoside should be started after appropriate cultures have been obtained. In nurseries where MRSA or methicillin-resistant *S. epidermidis* infections have been a problem, vancomycin should be substituted initially for the penicillin antibiotic.<sup>290,291</sup> If endocarditis caused by susceptible *Enterococcus* spp. is suspected, ampicillin should be added or substituted for the penicillinase-resistant penicillin. After the infecting organism is isolated and antibiotic susceptibilities have been determined, specific antimicrobial therapy can be instituted.

Four to 8 weeks of parenteral treatment is usually adequate, depending on the susceptibility of the organism, response to therapy assessed clinically by reduction or elimination of the observed vegetations, and laboratory response. C-reactive protein level often normalizes 2 to 3 weeks before erythrocyte sedimentation rate, and blood cultures are usually sterile after 3 to 5 days of effective therapy. *Candida* spp. may persist for weeks, however, despite the use of active antifungal drugs. Dosage and efficacy should be monitored weekly with clinical and bacteriologic response with or without serum antibiotic and bactericidal levels.<sup>291</sup> Determination of serum bactericidal titers (Schlichter test) is of uncertain value and has never been validated in neonatal endocarditis.<sup>291</sup> Efficacy of treatment may also be monitored with serial echocardiograms taken until vegetations remain stable in size or disappear.<sup>278,292,293</sup>

Intravascular catheters must be removed whenever possible, and the tip of the removed catheter should be cultured. Extremely large or mobile vegetations occluding an outflow tract or posing a high risk of embolism may have to be removed surgically.<sup>278,292</sup> In infants with right-sided endocarditis, demonstration of decreased pulmonary blood flow through the use of ventilation-perfusion scan can be



valuable in confirming the presence of emboli, particularly if there is clinical evidence of increasing respiratory effort and diminished peripheral oxygen saturation.

With the availability of echocardiography, improved clinical awareness, and early diagnosis, prognosis has improved. Although there were infrequent survivors before 1973, the first survivors with proven endocarditis were reported in 1983.<sup>278,293</sup> Approximately two thirds of subsequent cases have been cured. Death is usually the result of overwhelming sepsis, often in conjunction with cardiac failure. Early reconstructive surgery for infants who fail medical management may be helpful but has been reported in only a few cases.<sup>294,295</sup>

Inspection of the heart at autopsy has shown the mitral valve to be infected, alone or in combination with other valves, in about half of patients. The tricuspid valve was involved in 12 infants, the pulmonary valve in 7, the aortic valve in 6, infected mural thrombi in 12, and an unspecified site in 3. Microscopic examination of valve cusps has revealed the characteristic lesions of endocarditis, with multiple small, confluent, friable vegetations composed principally of bacteria and thrombi surrounded by inflammatory exudate.<sup>35,279</sup> On gross inspection, these vegetations are easily confused with noninflammatory lesions, such as those of nonbacterial thrombotic endocarditis, blood cysts, developmental valvular defects, or hemangiomas or other vascular anomalies. Cases described as fetal endocarditis in the literature are almost certainly examples of these types of lesions.<sup>296,297</sup>

## Pericarditis

Purulent pericarditis is a very unusual complication of neonatal sepsis. Approximately 20 cases of proven infectious origin have been reported within the past 60 years. *S. aureus*<sup>298</sup> and *E. coli*<sup>299</sup> have been the etiologic agents reported most commonly, but cases caused by *Haemophilus influenzae*, *Salmonella* spp., *Klebsiella*, *P. aeruginosa*, *Candida* spp., and *Mycoplasma hominis* have also been described.

Virtually every infant with pericarditis has associated septic foci; pneumonia and multiple pulmonary abscesses are the most common sites. Involvement of pericardium may occur by direct extension from adjoining lung abscesses or by hematogenous spread of bacteria. The presence of infectious processes elsewhere is sufficiently frequent to warrant the suggestion that pericarditis should be suspected in all infants who develop clinical signs of "heart failure" or a sudden increase in the size of the cardiac silhouette during the course of a purulent infection, such as meningitis, pneumonia, or omphalitis.<sup>300</sup>

Neonates with bacterial pericarditis generally present with signs and symptoms suggesting sepsis and respiratory distress. Poor feeding, listlessness, emesis, or abdominal distention may be seen in the presence of tachypnea, tachycardia, and cyanosis of various degrees. More specific signs of cardiac involvement become apparent with the accumulation of increasing amounts of pericardial effusion. The clinical findings of cardiac tamponade are extremely subtle and difficult to differentiate from the findings of myocardial disease with right-sided heart failure. A rapid pulse, quiet precordium, muffled heart sounds, neck vein distention, and hepatomegaly are findings common to both entities. More specific signs

of tamponade, such as narrow pulse pressure or respiratory variations in pulse volume of greater than 20 mm Hg (i.e., pulsus paradoxus), are technically difficult to obtain in neonates without an arterial catheter in place. A pericardial friction rub is absent in greater than 50% of older infants and children and in most neonates with purulent pericarditis.

Rapid enlargement of the cardiac silhouette, a globular heart shape with widening of the base on tilting, and diminished cardiac pulsation on fluoroscopic examination are of little value in differentiating pericardial effusion from cardiac dilatation.<sup>301</sup> The early ST segment elevation and subsequent T wave inversion seen on electrocardiogram reflect subepicardial damage or inflammation and are similar to changes seen with primary myocarditis. Diminution in the amplitude of the QRS complex by fluid surrounding the heart is not a constant finding. Confirmation of the presence of a pericardial effusion is usually obtained by two-dimensional echocardiography.<sup>301</sup> In some cases, CT or MRI can also be helpful in delineating the extent of a pericardial effusion<sup>302</sup>; on occasion, pericardial fluid is found incidental to the chest or abdominal scanning. Additional causes of neonatal pericardial effusion other than purulent disease include viral pericarditis, intrapericardial teratoma, maternal lupus, immune and nonimmune fetal hydrops, congenital diaphragmatic defects, chylopericardium, and central venous catheter perforation of the right atrium.

A definitive diagnosis of purulent pericarditis can be made only by obtaining fluid at surgery or through needle aspiration. Care and experience are necessary to facilitate aspiration while avoiding the risks of cardiac puncture or laceration.<sup>300</sup> Accurate monitoring of needle position can usually be obtained through CT guidance, with echocardiographic or fluoroscopic imaging, or by attaching the exploring electrode (V lead) of an electrocardiograph to the needle and by looking for injury current if contact is made with the epicardial surface of the heart.

When fluid is obtained, it should be sent for analysis to the laboratory in a laboratory-approved container appropriate for aerobic and anaerobic culture, mycobacteria, and fungi. In addition to cell count and protein and glucose levels, Gram and acid-fast stains should be performed with cultures for bacteria, viruses, mycobacteria, and fungi. Rapid identification of bacterial antigens by latex agglutination or by counterimmunoelectrophoresis of pericardial fluid, urine, or serum may also help to establish an etiologic diagnosis. Specialized testing for rare bacterial, viral, or fungal organisms by molecular methods may be available by request in specialized (research) or reference laboratories.

Purulent pericarditis is a medical and surgical emergency. Therapy must be directed toward relief of the cardiac tamponade through adequate pericardial drainage and toward resolution of the infection. Both modes of treatment are essential for successful therapy for bacterial pericarditis in the newborn; recovery cannot be expected from treatment with antibiotics alone. Although repeated needle aspirations or catheter drainage<sup>303</sup> may be sufficient, the frequent occurrence of loculations of pus, particularly with staphylococcal infection, suggests that open surgical pericardiostomy is the method of choice to achieve adequate drainage.

Initial therapy should be based on results of Gram stain or antigen detection tests of the pericardial fluid. If no organisms

can be identified, treatment can be started with penicillinase-resistant penicillin and an aminoglycoside (or extended-spectrum cephalosporin) until definitive culture and susceptibility data are available. In nurseries where MRSA infection has been a problem, vancomycin should be substituted for penicillin. Despite aggressive management, the prognosis of neonatal purulent pericarditis remains very poor.

## Mediastinitis

Purulent mediastinitis abscess in the neonate is a very rare condition that can be acquired through bloodborne dissemination of organisms, or by direct extension from a focus of infection in an adjacent retropharyngeal abscess, pleural or pulmonary abscess, vertebral osteomyelitis, or a complication of thoracic surgery.<sup>304-307</sup> *S. aureus* is the most frequently identified pathogen, but mediastinal infections with *S. pneumoniae*, *Clostridium* spp., and *E. coli* have also been reported.

Traumatic perforation of the posterior pharynx or esophagus, often the result of resuscitative efforts in infants involving endotracheal or gastric intubation, produces a potential site for entry of microorganisms.<sup>308,309</sup> Retropharyngeal abscess,<sup>310</sup> an infected pseudodiverticulum, or pyopneumothorax may occur as a consequence; purulent mediastinitis has been reported as a complication.<sup>311</sup> At least one case of mediastinitis has occurred as the result of overly vigorous passage of a nasogastric tube through an atretic esophageal pouch.<sup>312</sup> Low (intrathoracic) perforations are said to have a higher risk of mediastinitis and abscess formation than perforations in the cervical region.<sup>308</sup>

Early symptoms are nonspecific and are similar to symptoms of any septic process in a neonate. As purulent fluid accumulates in the mediastinum, it places increasing pressure on the esophagus, trachea, and tributaries of the superior vena cava and thoracic duct, bringing about rapid development of dysphagia, dyspnea, neck vein distention, and facial cyanosis or edema. To maintain a patent tracheal airway, an affected infant lies in an arched position with head extended in a manner very similar to that seen in neonates with congenital vascular ring. A halting, inspiratory, staccato type of breathing, probably because of pain, is also characteristic. Ultimately, the abscess may point on the anterior chest wall or in the suprasternal notch.

Usually, mediastinitis is first suspected when widening of the mediastinum is observed on a chest radiograph obtained for evaluation of respiratory distress. Forward displacement of the trachea and larynx may accompany these findings when retropharyngeal abscess is associated with mediastinitis. Infection after traumatic perforation of the esophagus or pharynx is often accompanied by pneumomediastinum with or without a pneumothorax.<sup>308,312</sup>

Contrast studies performed to define the cause of respiratory or feeding difficulties in infants with mediastinitis may result in flow of radiopaque fluid into an esophageal laceration, mimicking the findings of an atresia, duplication, or diverticulum of the esophagus.<sup>308,309</sup> In such cases, endoscopy often shows a mucosal tear, confirming the diagnosis.<sup>309</sup>

Treatment should be directed toward establishment of drainage and relief of pressure on vital structures

through a mediastinotomy and placement of drainage tubes. A tracheostomy or endotracheal tube may be necessary for maintenance of an adequate airway. Initial empirical antimicrobial therapy with clindamycin (or metronidazole), ampicillin, and an aminoglycoside (or extended-spectrum cephalosporin) and a  $\beta$ -lactam plus  $\beta$ -lactamase inhibitor combination should be started after cultures of the blood and all other clinically indicated cultures have been obtained. More limited empirical antibiotic therapy can be provided with a  $\beta$ -lactam and  $\beta$ -lactamase inhibitor combination alone, such as piperacillin plus tazobactam, ampicillin plus sulbactam, ticarcillin plus clavulanate, or meropenem. Specific therapy can subsequently be determined by the results of bacteriologic studies of the cultures or purulent fluid obtained at surgery.

## Esophagitis

The esophagus is infrequently a focus for infection of the fetus or newborn. Esophageal atresia is associated with congenital rubella (see Chapter 29). Severe esophagitis has also been reported in neonates with congenital cytomegalovirus infection.<sup>313</sup> The esophagus may be involved in infants with congenital Chagas disease, identified by signs of dysphagia, regurgitation, and megaesophagus.<sup>314</sup> Esophageal disease may follow mediastinitis in the neonate (discussed earlier). Only occasional cases of bacterial esophagitis in a neonate have been reported; a 940-g infant boy developed signs of sepsis on the fifth day of life and died 5 hours later.<sup>315</sup> Premortem blood cultures were positive for *Bacillus* spp. Examination at autopsy revealed histologic evidence of esophagitis with pseudomembranous necrosis of squamous epithelium and many gram-positive bacilli. No other focus of infection was evident.

## Infections of Endocrine Organs

Endocrine glands other than the adrenal are rarely involved in fetal or neonatal infection. Nelson<sup>316</sup> reported neonatal suppurative thyroiditis in a term Laotian infant. The infant presented with a left anterior neck mass at 3 days of age. At surgery, a cystic mass within the left lobe of the thyroid was identified. Purulent material within the mass grew viridans streptococci and nonhemolytic streptococci.

Orchitis caused by *S. enteritidis* was described in a 10-week-old neonate.<sup>317</sup> The infant presented with symptoms of sepsis and diarrhea, subsequently developing unilateral scrotal swelling and erythema on the fifth day after onset of illness. Ultrasound examination of the testis showed a patchy increased echo intensity; the diagnosis was confirmed at exploratory surgery to rule out testicular torsion.

## Infections of the Salivary Glands

Neonatal infections of salivary glands are uncommon; although rare, involvement of the parotid is the most frequent,<sup>318,319</sup> and submandibular gland infection is

infrequent.<sup>320</sup> Most infections are caused by *S. aureus*, but *E. coli*, *P. aeruginosa*, and GBS have also been implicated in suppurative parotitis. Oral anaerobic bacteria, including *Bacteroides* spp. and *Peptostreptococcus* spp., may be found in mixed or isolated infections in more than half of cases.<sup>318</sup> Infections of the salivary glands occur more frequently in premature and male infants<sup>319</sup> and most commonly manifest during the second week of life. The oral cavity is the probable portal of entry for the infecting organism. Blood-borne bacteria may invade the salivary glands, however. Dehydration with resultant decreased salivary flow may be a predisposing cause in some infants.

The clinical manifestations of salivary gland infection include fever, anorexia, irritability, and failure to gain weight. There may be swelling, tenderness, or erythema over the involved gland. Purulent material may be expressed from the ductal opening with or without gentle pressure over the gland.

The diagnosis is made by culture or Gram stain of the pus exuding from the duct or by percutaneous aspiration of a fluctuant area. If microscopic examination of the Gram stain does not suggest a responsible pathogen, initial antibiotic therapy should be directed against *S. aureus*, *E. coli*, and *P. aeruginosa* (i.e., penicillinase-resistant penicillin or vancomycin plus an aminoglycoside or extended-spectrum cephalosporin with activity against *Pseudomonas* organisms). If there is a strong suspicion of involvement with anaerobic bacteria (i.e., negative aerobic cultures or failure to respond to therapy directed at aerobic pathogens), consideration should be given to adding or substituting antibiotics appropriate for anaerobic bacteria (e.g., clindamycin, metronidazole in combination with other antibiotics, or a  $\beta$ -lactam and  $\beta$ -lactamase antibiotic combination alone). The duration of therapy should extend throughout the period of inflammation and 3 to 5 days after signs of local inflammation have disappeared. Incision and drainage often may be required; surgical drainage should be considered if there is not a prompt response to therapy within 72 hours or if the gland becomes fluctuant. When considering incision and drainage, careful attention to preservation of the function of overlying motor branches of cranial nerve VII is important.

## Infections of the Skin and Subcutaneous Tissue

Bacterial infections of the skin of the newborn may manifest as maculopapular rash, vesicles, pustules, bullae, abscesses, cellulitis, impetigo, erythema multiforme, and petechiae or purpura. In a review of 2836 neonatal infections in Finland, only 6 were characterized as cellulitis.<sup>321</sup> Most infections of skin, including bullous impetigo, chronic furunculosis, scalded skin syndrome, and breast abscesses, are caused by *S. aureus* and often MRSA (see Chapter 14). Cellulitis frequently accompanied by adenitis and bacteremia may be caused by GBS (see Chapter 12). Cutaneous infections caused by many other bacteria are discussed in this section; however, most microorganisms that cause disease in the neonate may produce cutaneous infections, and those infections are discussed in other chapters when relevant. For additional information on bacterial infections of the neonatal skin the reader is referred to a textbook, *Neonatal*

*Dermatology* by Eichenfield and colleagues,<sup>322</sup> the chapter of Swartz and Weinberg,<sup>323</sup> and a review by Frieden.<sup>324</sup> Excellent color photographs are included in the *Color Atlas of Pediatric Dermatology* by Weinberg and coworkers.<sup>325</sup>

## PATHOGENESIS

The skin of the newborn has unique characteristics, including absent microflora at birth; the presence of vernix caseosa; a less acid pH than that of older children; and often the presence of surgical wounds, including the severed umbilical cord, a circumcision site, and catheter wounds. Cutaneous bacterial infection may be a primary event or the result of systemic infection. Septicemic embolic infection may occur at widely separated sites, whereas local infections often occur at a site with an identifiable predisposing cause. Procedures resulting in breaks in the cutaneous continuity, such as forceps abrasions or wounds at fetal electrodes or at venipuncture sites, may be readily identified. The necrotic umbilical cord is a site for proliferation of microorganisms that may invade local tissues.

Infection of the circumcision site remains a concern because it is the most common surgical procedure in infants in the United States. Speert<sup>326</sup> found that many circumcision practitioners in the 19th century frequently disregarded cleanliness. Operators were frequently uneducated, were dirty, and often spat on their instruments. Erysipelas, tetanus, and diphtheria have long been recognized as complications of unsterile surgical technique performed on newborns. In a now obsolete and prohibited part of the Orthodox Jewish circumcision ritual, the operator applied his lips to the fresh circumcision wound and sucked a few drops of blood. Such practices were responsible for transmission of syphilis and tuberculosis in neonates in the past. In one report,<sup>327</sup> a 4-month-old infant presented with a penile ulcer, bilateral inguinal adenopathy, and a draining inguinal sinus caused by *Mycobacterium tuberculosis* after the “barber” spat on his razor before circumcision. Subsequent case reports of severe infection after circumcision include bacteremia related to GBS,<sup>328</sup> staphylococcal scalded skin syndrome,<sup>329</sup> necrotizing fasciitis,<sup>330</sup> and bullous impetigo.<sup>331</sup> Circumcision infection is uncommon, but local spread of infection may be devastating and lead to systemic infection.

Intrapartum fetal monitoring with scalp electrodes and intrauterine pressure catheters and measurements of fetal blood gases through scalp punctures have been associated with infections related to herpesvirus (see Chapter 27), *Mycoplasma* (see Chapter 20), and various aerobic and anaerobic bacteria. Bacterial infections have included pustules, abscesses, and fasciitis.<sup>331-334</sup> Infection rates are relatively low (0.1%–4.5%)<sup>332,333</sup>; however, severe infections, including fasciitis, meningitis, and osteomyelitis, have occurred as severe complications.<sup>335,336</sup> A review<sup>334</sup> of causative organisms in fetal scalp monitor infections found that 61% of infections were polymicrobial, involving anaerobic bacteria, aerobic gram-positive cocci, and gram-negative bacilli.

A multitude of specific virulence factors may be important determinants of disease. Some phage types of *S. aureus* are responsible for local tissue damage and systemic disease; other staphylococci elaborate toxins that result in bullae and other cutaneous pathology. Groups A and B



streptococci are responsible for cellulitis and impetigo in infants. *P. aeruginosa* may invade and proliferate in small blood vessels, causing local necrosis and eschar formation (i.e., ecthyma gangrenosum). Infections with *Clostridium* spp. cause disease in devitalized tissues such as the umbilical stump.<sup>337</sup>

## MICROBIOLOGY

The skin of the infant is colonized initially by microorganisms present in the maternal birth canal. The skin of infants delivered by cesarean section is usually sterile at birth. After birth, microorganisms may be transferred to the skin during handling by the parents and nursery personnel. The prevalent organisms on the skin during the first few days of life include coagulase-negative staphylococci, diphtheroids, and gram-negative enteric bacilli (including *E. coli*).<sup>338</sup> The umbilicus, genitalia, and adjacent skin areas (groin and abdomen) are colonized first; organisms then spread to the nose, throat, conjunctivae, and other body sites. Organisms present in the nursery environment colonize neonatal skin after a few days in the nursery. *S. aureus*, GBS, and various species of gram-negative bacilli may be present, but the microbiologic flora differs among nurseries and from time to time in the same nursery. Use of soaps and antiseptic solutions modifies the flora on the skin of the newborn. Hexachlorophene decreases colonization with staphylococci and diphtheroids, but gram-negative organisms are unaffected or may increase after use of this agent.<sup>339</sup>

In a 4-year survey (2001-2005) of staphylococcal infections in one center, 89 neonates were infected with staphylococci, and 61 (68.5%) infections were caused by MRSA; 30% of MRSA and methicillin-susceptible *S. aureus* infections manifested with pustular lesions, most often in the groin.<sup>340</sup> Cellulitis or abscess developed with 20% of MRSA and 32% of methicillin-susceptible *S. aureus* lesions, and 13% of lesions developed into an invasive infection (bacteremia, urinary tract infection). Also, infants with MRSA were more likely to have a mother with a history of skin infection (21% vs. 4%). Other investigators have attempted to eradicate high colonization and disease rates in neonatal nurseries with the use of bacteriostatic agents applied to the umbilical cord. In one study with a high rate of MRSA impetigo, 0.3% triclosan (Bacti-Stat) was not effective in slowing the progress of the epidemic.<sup>341</sup> In this epidemic, 22 infants were affected, and all but 2 of the affected infants were circumcised, suggesting that the colonization of the surgical site facilitated invasion of the skin.

## EPIDEMIOLOGY

Infant boys are more susceptible to skin infections caused by *S. aureus* than girls. Thompson and coworkers<sup>342</sup> showed that boys were colonized more frequently in every body site cultured, including the nose, groin, rectum, and umbilicus. Their review of studies indicated that in England, the United States, and Australia, approximately 50% more boys had skin lesions than girls. Although the incidence of breast abscesses is equal in boys and girls during the first 2 weeks of life, such abscesses are more frequent thereafter in girls.<sup>343</sup> Hormone production in the female infant after the second week might account for the increase in abscesses of the breast.

Infections caused by MRSA that involve the skin of children and neonates have markedly increased. The *mecA* gene responsible for resistance to oxacillin and nafcillin is often closely linked to a gene responsible for skin invasion. Before 1997, epidemic MRSA infections occurred in neonatal units involving infections of the respiratory tract, nasopharynx, gastrointestinal tract, eye, blood, wounds, or umbilicus.<sup>344</sup> These infections were usually restricted to single nurseries and involved a single genetic variant of MRSA. Since 1990, MRSA infections acquired in the community have been reported with increased frequency,<sup>345</sup> including in infants 2 weeks of age. Of these infections, 91% have involved the skin and soft tissues.

Seasonal variation in the frequency of neonatal skin infections has been reported by Evans and coworkers,<sup>346</sup> who conducted a series of studies at Harlem Hospital in New York. The prevalence of *S. aureus*, *E. coli*, and streptococci in the nares and umbilicus of infants was lowest in the autumn and usually highest in the summer or spring. No seasonal variation was observed for *S. epidermidis* or *Enterobacter* spp. The investigators concluded that seasonal differences must be considered in investigations of bacterial colonization of the newborn skin and that high humidity may favor gram-negative colonization.

The time of onset of skin lesions associated with sepsis may be early (during the first week of life) or late (several weeks or months after birth). Disease acquired in the nursery usually becomes apparent after 5 days of age. Many skin lesions do not appear until after the infant has left the nursery; the observed incidence of skin disease caused by bacteria should include surveillance of infants in the home during the first month of life. Physicians responsible for neonatal care must be alert to the unusual occurrence of skin lesions. The introduction of a new and virulent bacterium, an alteration in technique, or the use of contaminated materials must be considered as possible causes of an increased incidence of such infections.

## CLINICAL MANIFESTATIONS

Infants who have skin infections that remain localized that are not invasive or part of a systemic infection have few general signs of disease, such as fever, alteration in feeding habits, vomiting, or diarrhea. These signs may be present when significant tissue invasion occurs, as in abscesses or extensive cellulitis. Cutaneous manifestations that result from infectious diseases are listed in Table 10-4.

Among the common and least specific lesions are maculopapular rashes; these rashes may be caused by viruses (measles, rubella, or enteroviruses), fungi (*Candida* spp.), or bacteria (streptococci or staphylococci), or they may be unassociated with any infectious process. Erythema multiforme lesions have been observed in cases of sepsis related to *S. aureus*<sup>347</sup> and *P. aeruginosa*.<sup>348</sup> Cellulitis, erysipelas, and impetigo are usually associated with streptococcal infection (group A or B),<sup>349</sup> although impetigo caused by *S. aureus* or *E. coli* has also been reported in infants. Vesicles, commonly associated with infections by herpesviruses, also are seen occasionally during early stages of skin lesions caused by *S. aureus*, *H. influenzae*<sup>350</sup> and *P. aeruginosa*. GBS,<sup>351</sup> *S. aureus*, *P. aeruginosa*, herpes simplex virus, and *T. pallidum* may also be responsible for bullous lesions. Pustules

**Table 10-4** Manifestations and Etiologies of Infections of the Skin in Newborns

Clinical Manifestation	ETIOLOGIC AGENT	
	Bacterial	Nonbacterial
Maculopapular rash	<i>Treponema pallidum</i> *† <i>Listeria monocytogenes</i> <i>Streptococcus</i> * <i>Staphylococcus</i>	Measles virus* Rubella virus* Enteroviruses* Molluscum contagiosum <i>Candida</i> spp.*
Cellulitis (erysipelas)	β-Hemolytic streptococci <i>Achromobacter</i> spp.	
Impetigo	β-Hemolytic streptococci <i>Staphylococcus aureus</i> * <i>Escherichia coli</i>	
Erythema multiforme	β-Hemolytic streptococci <i>S. aureus</i> * <i>Pseudomonas aeruginosa</i>	
Vesicular or bullous lesions	<i>S. aureus</i> * <i>P. aeruginosa</i> <i>T. pallidum</i> <i>L. monocytogenes</i>	Herpes simplex virus*† Cytomegalovirus* Varicella virus*† Coxsackieviruses* <i>Candida</i> spp.* <i>Aspergillus</i> spp.* <i>Drosophila</i> larvae <i>Sarcoptes scabiei</i>
Pustular rashes	<i>S. aureus</i> * <i>L. monocytogenes</i> * <i>Haemophilus influenzae</i>	
Ecthyma gangrenosum	<i>P. aeruginosa</i>	
Abscesses and wound infections	<i>S. aureus</i> * <i>Mycoplasma hominis</i> * <i>Staphylococcus epidermidis</i> * β-Hemolytic streptococci <i>E. coli</i> <i>Klebsiella</i> spp. <i>Proteus mirabilis</i> <i>P. aeruginosa</i> <i>Salmonella</i> spp. <i>Serratia marcescens</i> <i>H. influenzae</i> <i>Haemophilus parainfluenzae</i> <i>Neisseria gonorrhoeae</i> <i>Gardnerella vaginalis</i> <i>Bacteroides</i> spp.	<i>Candida</i> spp.*
Petechiae, purpura, and ecchymoses	Gram positive and gram-negative bacteria with sepsis <i>L. monocytogenes</i> <i>Streptococcus pneumoniae</i> <i>T. pallidum</i> *†	Rubella virus*† Cytomegalovirus*† Herpes simplex virus*† Coxsackievirus B*† <i>Toxoplasma gondii</i> *†

\*See appropriate chapter for further discussion.

†Including infections acquired in utero.

commonly occur in staphylococcal diseases but also occur in infections caused by *L. monocytogenes* and, rarely, in skin infections with *H. influenzae*.

Ecthyma gangrenosum is typically a local manifestation of infection with *P. aeruginosa*.<sup>352-354</sup> Lesions begin as a vesicular eruption on a wide erythematous base. Vesicles rupture and form an indurated black eschar, followed by larger, sharply demarcated, painless necrotic areas, resulting from a small vessel vasculitis with necrosis of the adjacent tissue.

The organisms are present in purulent material underlying the necrotic membrane. These lesions are particularly more common adjacent to nose, lip, ear, mouth, and perineum, resulting in avascular necrosis and loss of tissue. *P. aeruginosa* may be grown in pure culture from blood and lesions. Ecthyma is relatively specific for *Pseudomonas* infections, but similar or identical lesions have rarely been described in infections caused by *S. aureus*, *Aeromonas hydrophila*, *E. coli*, *Aspergillus* spp., or *Mucor* spp.<sup>355</sup>

Many infants with *Candida* infections have cutaneous manifestations. Baley and Silverman<sup>356</sup> described 18 infants with systemic candidiasis; 8 had a burnlike truncal erythema, and 9 other infants had typical candidal diaper rashes or maculopapular rashes of the axillae or neck. A case of ecthyma gangrenosum caused by *Candida* infection in a 12-day-old neonate was reported.<sup>357</sup>

Abscesses of the skin and subcutaneous tissue are usually caused by *S. aureus* and, less frequently, by group A streptococci, GBS, or gram-negative enteric bacilli. Community-acquired MRSA organisms are even more likely to produce skin infections with abscess formation. Organisms that colonize the skin over an area that has been disrupted by an abrasion or other wound may invade the subcutaneous tissue and produce an abscess. *Haemophilus* spp., *Gardnerella vaginalis*, *Bacteroides* spp., molluscum contagiosum, *Drosophila* myiasis, scabies, and *Candida* are examples of diverse causes of cutaneous abscesses; virtually any bacterial, fungal, or parasitic agent that is normally or transiently on skin may become a pathogen. *E. coli*, *Klebsiella* spp., *P. aeruginosa*, *N. gonorrhoeae*, and *B. fragilis* have caused wound infections in infants whose scalps were lacerated by forceps, fetal electrodes, or instruments used for obtaining blood from the scalp in utero.

A cephalhematoma may become infected during sepsis or from manipulation of the cephalhematoma,<sup>358,359</sup> such as through diagnostic or therapeutic needle puncture or by puncture from a fetal monitor. The infection may be associated with meningitis<sup>360</sup> or with osteomyelitis of the underlying skull.<sup>361</sup>

*S. aureus* is the most frequent etiologic agent in breast abscess, but gram-negative enteric bacilli are occasionally identified. Of 36 cases with mastitis seen in Dallas, Texas, during a 16-year period, 32 cases were caused by *S. aureus*, 1 was caused by *E. coli*, and 2 were caused by *Salmonella* spp.; both *E. coli* and *S. aureus* were isolated from one abscess.<sup>343</sup> At Children's Hospital in Boston from 1947 to 1983, 41 cases of mastitis in neonates were managed.<sup>362</sup> *S. aureus* was responsible for 29 of 34 cases with an identifiable bacterial pathogen. All cases occurred in term infants during weeks 1 to 5 of life. Bilaterality and extramammary foci were rare. One third of infants were febrile, and most had elevated white blood cell counts (>15,000 cells/mm<sup>3</sup>). Brook<sup>363</sup> found that 5 of 14 breast abscesses contained anaerobic bacteria (i.e., *Bacteroides* spp. and *Peptostreptococcus*), but *S. aureus*, GBS, or enteric bacteria predominated; anaerobic bacteria occurred alone in only 2 of 14 cases.

Omphalitis is defined by the presence of erythema or serous or purulent discharge from the umbilical stump or periumbilical tissues. A review by Cushing<sup>364</sup> provided a useful discussion of the pathophysiology, microbiology, diagnosis, and management of omphalitis. The incidence of infection is more frequent in infants with low birth weight and infants

with complications of delivery. A survey of infants born at the Royal Women's Hospital in Brisbane, Australia,<sup>365</sup> identified an incidence of approximately 2% among term infants. The mean age of infants at presentation of omphalitis was 3.2 days. Perhaps because hexachlorophene bathing was used, gram-negative bacilli were more frequently associated with infection than gram-positive cocci. Microbiologic results are difficult to interpret, however, because swabs of the site of infection do not exclude surface contaminants, unless cultures are taken with extreme care and precision.

A series from the United States<sup>366</sup> found that periumbilical fasciitis was more frequent in boys but did not find that umbilical catheterization, low birth weight, or septic delivery was associated with a high risk; overall, the incidence of omphalitis was equal in boys and girls. In this series, omphalitis manifested as discharge, cellulitis, or fasciitis; gram-positive organisms were found in 94% of cultures, and gram-negative bacteria were found in 64%. *S. aureus* was the most frequent isolate, with *E. coli* and *Klebsiella* spp. the next most common. Group A streptococci have been responsible for nursery outbreaks that may include an indolent form of omphalitis characterized by erythema and oozing of the umbilical stump for days to weeks, accompanied by pustular lesions of the abdominal wall in some cases.<sup>367</sup> Neonatal tetanus usually occurs as a result of contamination of the umbilical wound by *Clostridium tetani* at delivery.

Acute necrotizing fasciitis is a bacterial infection of subcutaneous tissue and fascial sheath.<sup>368-370</sup> Infection can arise in an operative wound or in a focal infection, such as a breast abscess, after a procedure such as circumcision or insertion of a fetal monitor, or there may be no apparent predisposing cause. The trunk and extremities are the areas most commonly involved; inflammation spreads rapidly along fascial planes, producing thrombosis and extensive necrosis, with infarcts developing in overlying skin. Vesicles and bullae appear, and the skin may become blue-gray or black. Myositis and bacteremia may accompany fasciitis. Staphylococci, GBS,<sup>371</sup> *E. coli*, *P. aeruginosa*, anaerobic bacteria,<sup>372</sup> and mixed infections of gram-positive and gram-negative bacteria have been associated with this disease. The bacteria are present in skin lesions, deep fascia, and, in some cases, blood. The mortality remains high despite the use of fasciotomy, wide débridement, and antibiotics.

Perirectal abscesses may occur in newborns. In contrast to older children, most newborns with perirectal abscess do not have underlying immunodeficiency, although infants with acquired or congenital immunodeficiency often present with this condition. The most common causes of perirectal abscess are *S. aureus*, *E. coli*, or other enteric bacilli<sup>373,374</sup>; however, anaerobic bacteria can also be involved. *S. aureus* and enteric bacilli may be more common in infants and newborns.<sup>373</sup> Recent rectal surgery for conditions such as Hirschsprung disease or imperforate anus (myotomy or rectal dilatation) may be predisposing causes in infants; as in older children, neutropenia may be associated with an increased risk for perirectal abscess.

Otitis externa is uncommon in newborns. Victorin<sup>375</sup> described an outbreak of neonatal infections in which *P. aeruginosa* was cultured from seven infants with suppuration of the auditory canal. The author suggested that this outbreak was caused by contaminated bath water used in the nursery.

## DIAGNOSIS

The appearance of a skin lesion alone may be sufficiently typical to suspect certain etiologic agents (e.g., ecthyma gangrenosum), but more often, the appearance is nonspecific. A microbiologic diagnosis should be sought to provide specific therapy. The lesion and the surrounding tissue should be cleaned with 70% ethanol to prevent contamination from organisms that colonize the surface. If crusts are present, they should be lifted with a sterile swab to provide drainage, and cultures should be obtained from the base of the lesion.

Vesicles and pustules can be aspirated with a needle (20 gauge–25 gauge) attached to a syringe, or they can be opened and exudate can be collected on a sterile swab. In general, swabs are not preferred for specimen collection because swab materials bind or inactivate bacterial organisms. Aspiration of abscesses is important; more than one aspiration may be required because the suppurative focus may not be easily distinguished from the surrounding inflammatory tissue. Aspiration of the leading edge or point of maximal inflammation of an area of cellulitis may be valuable and should be performed if no other suppurative or purulent sites are available for culture. A small needle (25 gauge or 26 gauge) should be attached to a tuberculin or other small-volume syringe filled with 0.25 to 0.50 mL of sterile nonbacteriostatic saline; the needle should be inserted into the area of soft tissue to be sampled, with continuous, gentle aspiration applied to the syringe. If no fluid is returned to the syringe, a small amount of fluid should be injected and immediately aspirated back into the syringe. Collected material may be sent to the laboratory in the syringe for Gram stain and culture, or, alternatively, the contents may be washed into a tube of bacteriologic broth medium for transport and subsequent culture.

If swabs are used, care must be taken that the material does not dry before it is plated on bacteriologic media. Swabs preferentially should be directly inoculated or rinsed in bacteriologic media and immediately transported to the microbiology laboratory. Alternatively, they may be refrigerated or placed in appropriate transport media if more than a few hours will elapse before inoculation of media in the laboratory. Whenever sufficient material is available, on swabs or in liquid, several slides should be prepared for Gram staining.

It is often difficult to distinguish petechiae from vascular dilatation. Pressure with a glass slide on the border of the lesion is a simple and reliable method for detecting extravasation of red blood cells. If the lesion disappears on pressure, it is probably caused by dilation of small vessels, whereas persistence of the lesion after application of pressure indicates extravasation of red blood cells. Bacteria may be present in petechial lesions that occur in infants with bacterial sepsis. Blood obtained by aspiration or gentle scraping with a scalpel at the center of the petechiae may reveal the causative organism on Gram stain or culture.

## DIFFERENTIAL DIAGNOSIS

Sclerema neonatorum, milia, and erythema toxicum are noninfectious lesions that are often confused with infections of the skin.<sup>376</sup> Bullous and purpuric lesions may be caused by noninfectious disorders, including mast cell diseases (e.g., urticaria pigmentosa), histiocytosis X, acrodermatitis



enteropathica, dermatitis herpetiformis, epidermolysis bullosa, congenital porphyria, and pemphigus vulgaris. A syndrome of generalized erythroderma, failure to thrive, and diarrhea has been associated with various forms of immunodeficiency.<sup>377</sup>

Sclerema neonatorum is a diffuse, spreading, waxy hardness of the skin and subcutaneous tissue that occurs during the first weeks of life.<sup>378</sup> The subcutaneous tissue seems to be bound to underlying muscle and bone. This condition is usually seen on the thighs, buttocks, and trunk. Although associated with sepsis in some infants, sclerema also affects infants with dehydration, acidosis, and shock. Most evidence supports the hypothesis that sclerema is a manifestation of shock and insufficiency of the peripheral circulation. Skin biopsy histology shows trabecular thickening between adipocytes and a sparse inflammatory infiltrate of lymphocytes, histiocytes, and multinucleate giant cells. When it occurs in infants with generalized infection, sclerema is associated with a very poor prognosis; exchange transfusion may be one intervention associated with improved survival.

Milia are yellow or pearly white papules that are 1 mm in diameter and usually found on the face (especially the nose), scalp, upper aspect of trunk, and upper extremities, without significant racial or sex difference.<sup>379,380</sup> The lesion is a small cyst formed from retention of sebum in sebaceous glands, and because the cyst is capped by a shiny surface of epidermis, it may be confused with a small pustule. Congenital milia occur in 40% to 50% of newborns, present with a few or numerous lesions, and tend to resolve spontaneously within weeks to several months.<sup>379,380</sup> Milia may be less common and of delayed onset in premature newborns. These cysts may be distinguished from staphylococcal pustules by aspiration and Gram stain of the material.

Erythema toxicum consists of several types of lesions, including 1- to 3-mm, yellow-white papules or pustules on an erythematous base, erythematous macules, or diffuse erythema.<sup>381,382</sup> These lesions are usually present on the trunk but may involve the head and neck and extremities as well. Most lesions appear within the first hours of life and are uncommon after 2 days of age. Erythema toxicum is uncommon in low-birth-weight or premature infants. Affected infants have no signs of systemic illness or local irritation. A smear of the contents of pustules reveals the presence of eosinophils and an absence of bacteria. Other noninfectious pustular lesions of newborns include neonatal pustular melanosis, which is marked by a mixed infiltrate that has a predominance of neutrophils,<sup>383</sup> and infantile acropustulosis, which is characterized by an eosinophilic infiltration of the skin.<sup>384</sup>

Bullae may occur on the skin of the wrist or forearm and usually are caused by trauma.<sup>385</sup> Sucking of the extremity by the infant is believed to cause the bullae, which contain sterile serous fluid. Purpura may be caused by noninfectious conditions, including trauma; erythroblastosis fetalis; or, less frequently, coagulation disorders, maternal drug ingestion, congenital leukemia, and congenital Letterer-Siwe disease.

Diaper rash is primarily a contact dermatitis associated with soiling of the skin by urine and stool and is the most common cutaneous diagnosis in infants, although the incidence is decreasing in the era of disposable diapers.<sup>386,387</sup> The rash may occur as a mild erythema or scaling, a sharply demarcated and confluent erythema, or discrete

shallow ulcerations. A beefy red, confluent rash with raised margins, satellite (e.g., folliculitis) oval lesions, or discrete vesicular-pustular lesions indicates secondary invasion by *C. albicans*; risk factors include antibiotic use and diarrhea. Streptococcal and staphylococcal disease accounts for the majority of bacterial causes of diaper dermatitis. Because of its occluded, warm, and moist environment, the diaper area is a common site for the scabies mite in populations at risk. Systemic infectious illnesses, such as herpes simplex or syphilis, that manifest as disseminated neonatal rashes may be characterized early by typical lesions in the diaper area. Persistent diaper rash in the face of standard interventions should raise a concern of infantile psoriasis.

## TREATMENT

The treatment of localized skin lesions consists of the use of local antiseptic materials, systemic antimicrobial agents, and appropriate incision and drainage or débridement. Hexachlorophene (3% detergent emulsion) and chlorhexidine (4% solution) are valuable in cleaning small, abraded areas and discrete pustular lesions. Because of concern over its neurotoxicity and cutaneous absorption, hexachlorophene should not be used on large open areas of skin. Topical bacitracin or polysporin are additional options.

Systemic antibiotics should be considered for therapy whenever there is significant soft tissue infection with abscess or cellulitis. The specific antibiotic choice should be made on the basis of the microbiology of the lesion; streptococci may be treated effectively with penicillin G, ampicillin, or extended-spectrum cephalosporins (i.e., cefotaxime or ceftriaxone), whereas staphylococci generally must be treated with penicillinase-resistant penicillins or vancomycin. Infections caused by gram-negative enteric bacilli may be treated with aminoglycosides or extended-spectrum cephalosporins, based on the results of susceptibility testing. Infections caused by *Pseudomonas* organisms can be effectively treated with aminoglycosides or ceftazidime.

Local heat and moist dressings over areas of abscess formation may facilitate localization or spontaneous drainage. Indications for incision and drainage of abscesses in infants are the same as for the indications in older children and adults.

## PREVENTION

Prevention of local skin infections is best provided by appropriate routine hygiene, maintenance of the integrity of skin (i.e., avoidance of drying, trauma, or chemical contact), frequent diaper changes, and hygienic care of the umbilicus or other wounds or noninfectious skin inflammation. The following measures of skin care are recommended by the Committee of the Fetus and Newborn of the American Academy of Pediatrics<sup>388</sup> to prevent infection:

1. The first bath should be postponed until the infant is thermally stable.
2. Nonmedicated soap and water should be used; sterile sponges (not gauze) soaked in warm water may be used.
3. The buttocks and perianal should be cleaned with fresh water and cotton or with mild soap and water at diaper changes.

4. Ideally, agents used on the newborn skin should be dispensed in single-use containers.
5. No single method of cord care has proved to be superior, and none is endorsed.

Cord care may include application of alcohol, triple dye (i.e., brilliant green, proflavine hemisulfate, and crystal violet), or antimicrobial agents such as bacitracin. Alcohol hastens drying of the cord but is probably not effective in preventing cord colonization and omphalitis. A randomized study of triple dye, povidone-iodine, silver sulfadiazine, and bacitracin ointment showed comparability in antimicrobial control.<sup>389</sup> In a recent systematic review,<sup>390</sup> evidence supports topical application of chlorhexidine to reduce neonatal mortality and omphalitis in community and primary care settings in developing countries; although cord separation time may be increased, there is no evidence that it increases risk of subsequent morbidity or infection.

During nursery outbreaks of staphylococcal disease, daily hexachlorophene bathing of the diaper area<sup>391</sup> and umbilical cord care with 4% chlorhexidine solution<sup>392</sup> have shown efficacy for preventing further transmission.

## Conjunctivitis and Other Eye Infections

Conjunctivitis in the newborn usually results from one of four causes: infection with *N. gonorrhoeae*, infection with *S. aureus*, inclusion conjunctivitis caused by *Chlamydia trachomatis*, or chemical conjunctivitis caused by silver nitrate solution.<sup>393,394</sup> Less commonly, other microorganisms have been implicated as a cause of conjunctivitis, including group A streptococci, GBS, *S. pneumoniae*, *H. influenzae*, *P. aeruginosa*, *Moraxella* (*Neisseria*) *catarrhalis*, *Neisseria meningitidis*, *Neisseria cinerea*, *Corynebacterium diphtheriae*, *Pasteurella multocida*, *Clostridium* spp., herpes simplex virus, echoviruses, *M. hominis*, and *Candida* spp. Gonococcal and chlamydial conjunctivitis are reviewed in Chapters 15 and 19, respectively.

An epidemic of erythromycin-resistant *S. aureus* conjunctivitis affected 25 of 215 newborns during a 10-month period; control of the epidemic was achieved by identification of staff carriers and substitution of silver nitrate prophylaxis for erythromycin.<sup>395</sup> Cultures of the conjunctivae of neonates with purulent conjunctivitis and from the comparable eyes of a similar number of infants chosen as control subjects revealed significant differences, suggesting causality for viridans streptococci, *S. aureus*, *E. coli*, and *Haemophilus* spp.<sup>396,397</sup> MRSA infections may have an increased propensity to infect the eye. Conjunctivitis caused by MRSA was reported as the first case in an epidemic that eventually involved 14 neonates in a NICU, including multiple invasive infections and two deaths.<sup>398</sup> MRSA has also caused dacryocystitis<sup>399</sup> and keratitis<sup>400</sup> in neonates.

Infections related to *P. aeruginosa* warrant special attention. Although uncommon, pseudomonal conjunctivitis may be a devastating disease if not recognized and treated appropriately.<sup>401</sup> The infection is usually acquired in the nursery, and the first signs of conjunctivitis appear between the 5th and 18th days of life. At first, the clinical manifestations are localized to the eye and include edema and

erythema of the lid and purulent discharge. In some children, the conjunctivitis progresses rapidly, with denuding of the corneal epithelium and infiltration with neutrophils. With extension of the corneal infiltration, perforation of the cornea may occur. The anterior chamber may fill with fibrinous exudate, and the iris can adhere to the cornea. Subsequent invasion of the cornea by small blood vessels (pannus) is characteristic of pseudomonal conjunctivitis. The late ophthalmic complications may be followed by bacteremia and septic foci in other organs.<sup>402</sup>

A review by Lohrer and Belohradsky<sup>403</sup> of 16 cases of serious invasive eye infections in neonates included 13 caused by *P. aeruginosa*, whereas the others were cases of endophthalmitis caused by GBS and *S. pneumoniae*. Other opportunistic gram-negative pathogens associated with outbreaks of infections in nurseries may also include conjunctivitis as a part of the infection syndrome. Multiply antibiotic-resistant *S. marcescens* was responsible for 15 cases of pneumonia, sepsis, and meningitis and for 20 cases of conjunctivitis, cystitis, and wound infection over a 9-month period in a NICU.<sup>404</sup>

Dacryocystitis may complicate a congenital lacrimal sac distention (i.e., dacryocystocele) which may appear as early as the first week of life with edema and erythema of the lower lid. Purulent material emerged from the puncta after moderate pressure over the lacrimal sac; *S. marcescens* was grown from the material.

The physician responsible for management of a child with purulent conjunctivitis must consider the major causes of the disease and must be alert to rare pathogens. In hospitals that practice Credé method (i.e., silver nitrate application), purulent conjunctivitis during the first 48 hours of life is almost always caused by chemical toxicity.<sup>405</sup> After the first 2 days, the pus of an exudative conjunctivitis must be carefully examined by Gram stain for the presence of gram-negative intracellular diplococci, gram-positive cocci in clusters, and gram-negative bacilli. Appropriate cultures should be used for isolation of the organisms concerned. If smears are inconclusive and no pathogens are isolated on appropriate media, with persistent conjunctivitis, a diagnosis of inclusion or chlamydial infection is likely.<sup>405,406</sup>

The treatment approaches to staphylococcal and gonococcal conjunctivitis are discussed in Chapters 14 and 15. Chlamydial conjunctivitis is reviewed in Chapter 19. If infection with *Pseudomonas* spp. is suspected, treatment should be started at once with an effective parenteral antibiotic, such as an aminoglycoside (e.g., tobramycin, amikacin, or gentamicin) with or without an antipseudomonal penicillin or ceftazidime (see Chapter 37) and with a locally applied ophthalmic ointment. The use of subconjunctival gentamicin or other antipseudomonal aminoglycoside is of uncertain value; however, if the cornea seems to be extensively involved, there is a risk of rapid development of endophthalmitis, and the subconjunctival injection of antibiotics should be considered in consultation with an ophthalmologist. If the diagnosis is confirmed, this regimen is continued until the local signs of *Pseudomonas* infection resolve.

Recommendations for ocular chemoprophylaxis are discussed in Chapters 15 and 19. Additional information is available in the 2012 edition of the *Red book: report of the Committee on Infectious Diseases* published by the American Academy of Pediatrics.<sup>407</sup>

## References

1. Murphy FM, Baker CJ: Solitary hepatic abscess: a delayed complication of neonatal bacteremia, *Pediatr Infect Dis J* 7:414-416, 1988.
2. Guillois B, Guillemin MG, Thoma M, et al: Neonatal pleuropulmonary staphylococcal infection with multiple abscesses of the liver, *Ann Pediatr (Paris)* 36:681-684, 1989.
3. Dehner LP, Kissane JM: Pyogenic hepatic abscesses in infancy and childhood, *J Pediatr* 74:763-773, 1969.
4. Moss TJ, Pysker TJ: Hepatic abscess in neonates, *Am J Dis Child* 135:726-728, 1981.
5. Chusid MJ: Pyogenic hepatic abscess in infancy and childhood, *Pediatrics* 62:554-559, 1978.
6. Dineen P: Personal communication, New York, 1978, Cornell University College of Medicine.
7. Simeunovic E, Arnold M, Sidler D, et al: Liver abscess in neonates, *Pediatr Surg Int* 25:153-156, 2009.
8. Anagnostakis D, Kamba A, Petrochilou V, et al: Risk of infection associated with umbilical vein catheterization. A prospective study in 75 newborn infants, *J Pediatr* 86:759-765, 1975.
9. Smith RT, Platou ES, Good RA: Septicemia of the newborn; current status of the problem, *Pediatrics* 17:549-575, 1956.
10. Madsen CM, Secouris N: Solitary liver abscess in a newborn, *Surgery* 47:1005-1009, 1960.
11. Sabbaj J, Sutter VL, Finegold SM: Anaerobic pyogenic liver abscess, *Ann Intern Med* 77:627-638, 1972.
12. Potter E: *Pathology of the fetus and infant*, ed 3, Chicago, 1975, Year Book Medical Publishers.
13. Meyer WW, Lind J: Postnatal changes in the portal circulation, *Arch Dis Child* 41:606-612, 1966.
14. Hageman J, Shulman S, Schreiber M, et al: Congenital tuberculosis: critical reappraisal of clinical findings and diagnostic procedures, *Pediatrics* 66:980-984, 1980.
15. Hughesdon MR: Congenital tuberculosis, *Arch Dis Child* 21: 121-138, 1946.
16. Cantwell MF, Shehab ZM, Costello AM, et al: Brief report: congenital tuberculosis, *N Engl J Med* 330:1051-1054, 1994.
17. Abughali N, Van der Kuyp F, Annable W, et al: Congenital tuberculosis, *Pediatr Infect Dis J* 13:738-741, 1994.
18. Oppenheimer EH, Hardy JB: Congenital syphilis in the newborn infant: clinical and pathological observations in recent cases, *Johns Hopkins Med J* 129:63-82, 1971.
19. Venter A, Pettifor JM, Duursma J, et al: Liver function in early congenital syphilis: does penicillin cause a deterioration? *J Pediatr Gastroenterol Nutr* 12:310-314, 1991.
20. Lindsay S, Luke IW: Fatal leptospirosis (Weil's disease) in a newborn infant; case of intrauterine fetal infection with report of an autopsy, *J Pediatr* 34:90-94, 1949.
21. Chung HL, Tsao WC, Mo PS, et al: Transplacental or congenital infection of leptospirosis. Clinical and experimental observations, *Chin Med J (Engl)* 82:777-782, 1963.
22. Fuchs PC, Oyama AA: Neonatal relapsing fever due to transplacental transmission of *Borrelia*, *JAMA* 208:690-692, 1969.
23. Yagupsky P, Moses S: Neonatal *Borrelia* species infection (relapsing fever), *Am J Dis Child* 139:74-76, 1985.
24. Cascio A, Pantaleo D, Corona G, et al: Neonatal liver abscesses associated with candidemia: three cases and review of literature, *J Matern Fetal Neonatal Med* 27:743-749, 2014.
25. Pyrttek LJ, Bartus SA: Hepatic pyemia, *N Engl J Med* 272:551-554, 1965.
26. Sharma K, Kumar R: Solitary abscess of the liver in a newborn infant, *Surgery* 61:812-813, 1967.
27. Lipinski JK, Vega JM, Cywes S, et al: Falciform ligament abscess in the infant, *J Pediatr Surg* 20:556-558, 1985.
28. Brans YW, Ceballos R, Cassady G: Umbilical catheters and hepatic abscesses, *Pediatrics* 53:264-266, 1974.
29. Cohen HJ, Dresner S: Liver abscess following exchange transfusion for erythroblastosis fetalis, *Q Rev Pediatr* 16:148-149, 1961.
30. Elliott RI: The ductus venosus in neonatal infection, *Proc R Soc Med* 62:321-323, 1969.
31. Williams JW, Rittenberry A, Dillard R, et al: Liver abscess in newborn. Complication of umbilical vein catheterization, *Am J Dis Child* 125:111-113, 1973.
32. Santerne B, Morville P, Touche D, et al: Diagnosis and treatment of multifocal neonatal hepatic abscesses using echography, *Presse Med* 16:12-14, 1987.
33. Sarrut S, Alain J, Alison F: The early complications of umbilical vein perfusion in the premature infant, *Arch Fr Pediatr* 26:651-667, 1969.
34. Wiedersberg H, Pawlowski P: Pylephlebitis after umbilical vein catheterization {author's transl}, *Monatsschr Kinderheilkd* 128:128-135, 1980.
35. Scott JM: Iatrogenic lesions in babies following umbilical vein catheterization, *Arch Dis Child* 40:426-429, 1965.
36. Tariq AA, Rudolph N, Levin EJ: Solitary hepatic abscess in a newborn infant: a sequel of umbilical vein catheterization and infusion of hypertonic glucose solutions, *Clin Pediatr (Phila)* 16:577-578, 1977.
37. Axton JH: Amoebic proctocolitis and liver abscess in a neonate, *S Afr Med J* 46:258-259, 1972.
38. Botman T, Ruys PJ: Amoebic appendicitis in a newborn infant, *Trop Geogr Med* 15:221-224, 1963.
39. Heck W, Rehbein F, Reismann B: Pyogenic liver abscess in infancy, *Z Kinderchir(suppl 1)*49, 1966.
40. Morison JE: Umbilical sepsis and acute interstitial hepatitis, *J Pathol Bacteriol* 56:531, 1944.
41. Bernstein J, Brown AK: Sepsis and jaundice in early infancy, *Pediatrics* 29:873-882, 1962.
42. Parker RG: Jaundice and infantile diarrhoea, *Arch Dis Child* 33: 330-334, 1958.
43. Kandall SR, Johnson AB, Gartner LM: Solitary neonatal hepatic abscess, *J Pediatr* 85:567-569, 1974.
44. Cushman P, Ward OC: Solitary liver abscess in a neonate: complication of umbilical vein catheterisation, *Ir J Med Sci* 147:374-375, 1978.
45. Nars PW, Klco L, Fliegel CP: Successful conservative management of a solitary liver abscess in a premature baby, *Helv Paediatr Acta* 38:489-493, 1983.
46. Gwinn JL, Lee FA, Baker CJ, et al: Pyogenic liver abscess, *Am J Dis Child* 123:49-50, 1972.
47. Martin DJ: Neonatal disorders diagnosed with ultrasound, *Clin Perinatol* 12:219-242, 1985.
48. Halvorsen RA Jr, Foster WL Jr, Wilkinson RH Jr, et al: Hepatic abscess: sensitivity of imaging tests and clinical findings, *Gastrointest Radiol* 13:135-141, 1988.
49. Caron KH: Magnetic resonance imaging of the pediatric abdomen, *Semin Ultrasound CT MR* 12:448-474, 1991.
50. Weinreb JC, Cohen JM, Armstrong E, et al: Imaging the pediatric liver: MRI and CT, *AJR Am J Roentgenol* 147:785-790, 1986.
51. Pineiro-Carrero VM, Andres JM: Morbidity and mortality in children with pyogenic liver abscess, *Am J Dis Child* 143:1424-1427, 1989.
52. Diamant MJ, Stanley P, Kangaroo H, et al: Percutaneous aspiration and catheter drainage of abscesses, *J Pediatr* 108:204-208, 1986.
53. Rubinstein Z, Heyman Z, Morag B, et al: Ultrasound and computed tomography in the diagnosis and drainage of abscesses and other fluid collections, *Isr J Med Sci* 19:1050-1055, 1983.
54. Lee SH, Tomlinson C, Temple M, et al: Imaging-guided percutaneous needle aspiration or catheter drainage of neonatal liver abscesses: 14-year experience, *AJR Am J Roentgenol* 190:616-622, 2008.
55. Beaven DW: Staphylococcal peritonitis in the newborn, *Lancet* 1:869-871, 1958.
56. Fraga JR, Javate BA, Venkatesan S: Liver abscess and sepsis due to *Klebsiella pneumoniae* in a newborn. A complication of umbilical vein catheterization, *Clin Pediatr (Phila)* 13:1081-1082, 1974.
57. Reynolds TB: Medical treatment of pyogenic liver abscess, *Ann Intern Med* 96:373-374, 1982.
58. Loh R, Wallace G, Thong YH: Successful non-surgical management of pyogenic liver abscess, *Scand J Infect Dis* 19:137-140, 1987.
59. Shaw A, Pierog S: 'Ectopic' liver in the umbilicus: an unusual focus of infection in a newborn infant, *Pediatrics* 44:448-450, 1969.
60. Eklof O, Mortensson W, Sandstedt B: Suprarenal haematoma versus neuroblastoma complicated by haemorrhage. A diagnostic dilemma in the newborn, *Acta Radiol Diagn (Stockh)* 27:3-10, 1986.
61. Amodio J, Biskup D, Rivera R, et al: Tuberculous splenic abscess in a neonate with thrombocytopenia, *Pediatr Radiol* 35:887-890, 2005.
62. Kruger C, Malleyeck I, Naman N: Amoebic abscess of the spleen and fatal colonic perforation, *Pediatr Infect Dis J* 30:91-92, 2011.
63. Bowen A: Acute gallbladder dilatation in a neonate: emphasis on ultrasonography, *J Pediatr Gastroenterol Nutr* 3:304-308, 1984.
64. Brill PW, Winchester P, Rosen MS: Neonatal cholelithiasis, *Pediatr Radiol* 12:285-288, 1982.
65. Callahan J, Haller JO, Cacciarelli AA, et al: Cholelithiasis in infants: association with total parenteral nutrition and furosemide, *Radiology* 143:437-439, 1982.



66. Schirmer WJ, Grisoni ER, Gauderer MW: The spectrum of cholelithiasis in the first year of life. *J Pediatr Surg* 24:1064-1067, 1989.
67. Debray D, Pariente D, Gauthier F, et al: Cholelithiasis in infancy: a study of 40 cases. *J Pediatr* 122:385-391, 1993.
68. Neu J, Arvin A, Ariagno RL: Hydrops of the gallbladder. *Am J Dis Child* 134:891-893, 1980.
69. Peevy KJ, Wiseman HJ: Gallbladder distension in septic neonates. *Arch Dis Child* 57:75-76, 1982.
70. Saldanha RL, Stein CA, Kopelman AE: Gallbladder distention in ill preterm infants. *Am J Dis Child* 137:1179-1180, 1983.
71. Modi N, Keay AJ: Neonatal gallbladder distension. *Arch Dis Child* 57:562, 1982.
72. McGahan JP, Phillips HE, Cox KL: Sonography of the normal pediatric gallbladder and biliary tract. *Radiology* 144:873-875, 1982.
73. Haller JO: Sonography of the biliary tract in infants and children. *AJR Am J Roentgenol* 157:1051-1058, 1991.
74. Guthrie KJ, Montgomery GL: Infections with bacterium enteritidis in infancy with a triad of enteritis, cholecystitis, and meningitis. *J Pathol Bacteriol* 49:393, 1939.
75. Mateos-Corral D, Garza-Luna U, Gutierrez-Martin A: Two reports of acute neonatal acalculous cholecystitis (necrotizing cholecystitis) in a 2-week-old premature infant and a term neonate. *J Pediatr Surg* 41:e3-e5, 2006.
76. Arnsperger LA, Martin JG, Krempin HO: Acute noncalculous cholecystitis in children. Report of a case in seventeen day old infant. *Am J Surg* 100:103-106, 1960.
77. Ternberg JL, Keating JP: Acute acalculous cholecystitis. Complication of other illnesses in childhood. *Arch Surg* 110:543-547, 1975.
78. Wyllie R, Fitzgerald JF: Bacterial cholangitis in a 10-week-old infant with fever of undetermined origin. *Pediatrics* 65:164-167, 1980.
79. Becroft DM: Biliary atresia associated with prenatal infection by *Listeria monocytogenes*. *Arch Dis Child* 47:656-660, 1972.
80. Arena F, Romeo C, Manganaro A, et al: Bilateral neonatal adrenal abscess. Report of two cases and review of the literature. *Pediatr Med Chir* 25:185-189, 2003.
81. Ratnavel N, Farrer K, Sharland M, et al: Neonatal adrenal abscess revisited: the importance of raised inflammatory markers. *Ann Trop Paediatr* 25:63-66, 2005.
82. Blankenship WJ, Bogren H, Stadalnik RC, et al: Suprarenal abscess in the neonate: a case report and review of diagnosis and management. *Pediatrics* 55:239-243, 1975.
83. Carty A, Stanley P: Bilateral adrenal abscesses in a neonate. *Pediatr Radiol* 1:63-64, 1973.
84. Walker KM, Coyer WF: Suprarenal abscess due to group B *Streptococcus*. *J Pediatr* 94:970-971, 1979.
85. Francois A, Berterottiere D, Aigrain Y, et al: Neonatal *Proteus mirabilis* adrenal gland abscess. *Arch Fr Pediatr* 48:559-561, 1991.
86. Rajani K, Shapiro SR, Goetzman BW: Adrenal abscess: complication of supportive therapy of adrenal hemorrhage in the newborn. *J Pediatr Surg* 15:676-678, 1980.
87. Ohta S, Shimizu S, Fujisawa S, et al: Neonatal adrenal abscess due to *Bacteroides*. *J Pediatr* 93:1063-1064, 1978.
88. Bekdash BA, Slim MS: Adrenal abscess in a neonate due to gas-forming organisms: a diagnostic dilemma. *Z Kinderchir* 32:184-187, 1981.
89. Atkinson GO Jr, Kodroff MB, Gay BB Jr, et al: Adrenal abscess in the neonate. *Radiology* 155:101-104, 1985.
90. Gross M, Kottmeier PK, Waterhouse K: Diagnosis and treatment of neonatal adrenal hemorrhage. *J Pediatr Surg* 2:308-312, 1967.
91. Torres Simon JM, Figueras Aloy J, Vilanova Juanola JM, et al: Adrenal abscess in a neonate. *An Esp Pediatr* 31:601-602, 1989.
92. Mittelstaedt CA, Volberg FM, Merten DF, et al: The sonographic diagnosis of neonatal adrenal hemorrhage. *Radiology* 131:453-457, 1979.
93. Zamir O, Udassin R, Aviad I, et al: Adrenal abscess. *Pediatr Surg Int* 2:117-119, 1987.
94. Cohen MD: Clinical utility of magnetic resonance imaging in pediatrics. *Am J Dis Child* 140:947-956, 1986.
95. Etherington-Wilson W: Appendicitis in the newborn. Report on case 16 days old. *Proc R Soc Med* 38:186-187, 1945.
96. Puri P, O'Donnell B: Appendicitis in infancy. *J Pediatr Surg* 13:173-174, 1978.
97. Reuter G, Krause I: Appendicitis of the newborn infant. *Kinderarztl Prax* 43:289-292, 1975.
98. Parsons JM, Miscall BG, McSherry CK: Appendicitis in the newborn infant. *Surgery* 67:841-843, 1970.
99. Schaupp W, Clausen EG, Ferrier PK: Appendicitis during the first month of life. *Surgery* 48:805-811, 1960.
100. Stanley-Brown EG: Acute appendicitis during first five years of life. *Am J Dis Child* 108:134-138, 1964.
101. Fields IA, Naiditch MJ, Rothman PE: Acute appendicitis in infants; ten-year survey at the Los Angeles County Hospital and report of a case of perforated appendicitis in a fifteen-day-old infant with survival. *AMA J Dis Child* 93:287-305, 1957.
102. Norris WJ: Appendicitis in children; review of one thousand cases taken from the records of the Children's Hospital, Los Angeles. *West J Surg Obstet Gynecol* 54:183-192, 1946.
103. Snyder WH Jr, Chaffin L: Appendicitis during first two years of life; report on twenty-one cases and review of four hundred forty-seven cases from the literature. *AMA Arch Surg* 64:549-560, 1952.
104. Grosfeld JL, Weinberger M, Clatworthy HW Jr: Acute appendicitis in the first two years of life. *J Pediatr Surg* 8:285-293, 1973.
105. Massad M, Srouji M, Awdeh A, et al: Neonatal appendicitis: case report and a revised review of the English literature. *Z Kinderchir* 41:241-243, 1986.
106. Schorlemmer GR, Herbst CA Jr: Perforated neonatal appendicitis. *South Med J* 76:536-537, 1983.
107. Caralps-Riera JM, Cohn BD: Bowel perforation after exchange transfusion in the neonate: review of the literature and report of a case. *Surgery* 68:895-898, 1970.
108. Broadbent NR, Jardine JL: Acute appendicitis in a premature infant: a case report. *Aust N Z J Surg* 40:362-364, 1971.
109. Bryant LR, Trinkle JK, Noonan JA, et al: Appendicitis and appendiceal perforation in neonates. *Am Surg* 36:523-525, 1970.
110. Creery RD: Acute appendicitis in the newborn. *Br Med J* 1:871, 1953.
111. Hardman RP, Bowerman D: Appendicitis in the newborn. *Am J Dis Child* 105:99-101, 1963.
112. Kolb G, Schaeffer E: Perforating appendicitis in the first weeks of life. *Kinderarztl Prax* 23:1-4, 1955.
113. Meigher SC, Lucas AW: Appendicitis in the newborn; case report. *Ann Surg* 136:1044-1047, 1952.
114. Neve R, Quenville NF: Appendicitis with perforation in a 12-day-old infant. *Can Med Assoc J* 94:447-448, 1966.
115. Niforoushan MA: Fever and ascites in a newborn. *Clin Pediatr (Phila)* 14:878, 1975.
116. Parkhurst GF, Wagoner SC: Neonatal acute appendicitis. *N Y State J Med* 69:1929-1930, 1969.
117. Smith AL, MacMahon RA: Perforated appendix complicating rhesus immunization in a newborn infant. *Med J Aust* 2:602-603, 1969.
118. Walker RH: Appendicitis in the newborn infant. *J Pediatr* 51:429-434, 1957.
119. Trojanowski JQ, Gang DL, Goldblatt A, et al: Fatal postoperative acute appendicitis in a neonate with congenital heart disease. *J Pediatr Surg* 16:85-86, 1981.
120. Ayalon A, Mogilner M, Cohen O, et al: Acute appendicitis in a premature baby. *Acta Chir Scand* 145:285-286, 1979.
121. Golladay ES, Roskes S, Donner L, et al: Intestinal obstruction from appendiceal abscess in a newborn infant. *J Pediatr Surg* 13:175-176, 1978.
122. Hemalatha V, Spitz L: Neonatal appendicitis. *Clin Pediatr (Phila)* 18:621-622, 1979.
123. Tucci P, Holgersen L, Doctor D, et al: Congenital ureteropelvic junction obstruction associated with unsuspected acute perforated appendicitis in a neonate. *J Urol* 120:247-248, 1978.
124. Kwong MS, Dinner M: Neonatal appendicitis masquerading as necrotizing enterocolitis. *J Pediatr* 96:917-918, 1980.
125. Shaul WL: Clues to the early diagnosis of neonatal appendicitis. *J Pediatr* 98:473-476, 1981.
126. Lassiter HA, Werner MH: Neonatal appendicitis. *South Med J* 76:1173-1175, 1983.
127. Carol J, Creixell S, Hernandez JV, et al: Neonatal appendicitis. Report of a new case. *An Esp Pediatr* 20:807-810, 1984.
128. Bax NM, Pearse RG, Dommering N, et al: Perforation of the appendix in the neonatal period. *J Pediatr Surg* 15:200-202, 1980.
129. Heydenrych JJ, Du Toit DF: Unusual presentations of acute appendicitis in the neonate. A report of 2 cases. *S Afr Med J* 62:1003-1005, 1982.
130. Pathania OP, Jain SK, Kapila H, et al: Fatal neonatal perforation of appendix. *Indian Pediatr* 26:1166-1167, 1989.

131. Arora NK, Deorari AK, Bhatnagar V, et al: Neonatal appendicitis: a rare cause of surgical emergency in preterm babies, *Indian Pediatr* 28:1330-1333, 1991.
132. Arliss J, Holgersen LO: Neonatal appendiceal perforation and Hirschsprung's disease, *J Pediatr Surg* 25:694-695, 1990.
133. Kliegman RM, Fanaroff AA: Necrotizing enterocolitis, *N Engl J Med* 310:1093-1103, 1984.
134. Srouji MN, Buck BE: Neonatal appendicitis: ischemic infarction in incarcerated inguinal hernia, *J Pediatr Surg* 13:177-179, 1978.
135. Jancelewicz T, Kim G, Miniati D: Neonatal appendicitis: a new look at an old zebra, *J Pediatr Surg* 43:e1-e5, 2008.
136. Gross RE: *The surgery of infancy and childhood: its principles and techniques*, Philadelphia, 1953, WB Saunders.
137. Dennis JE, Rhodes KH, Cooney DR, et al: Nosocomial *Rhizopus* infection (zygomycosis) in children, *J Pediatr* 96:824-828, 1980.
138. Buschard K, Kjaeldgaard A: Investigation and analysis of the position, fixation, length and embryology of the vermiform appendix, *Acta Chir Scand* 139:293-298, 1973.
139. Jones WR, Kaye MD, Ing RM: The lymphoid development of the fetal and neonatal appendix, *Biol Neonate* 20:334-345, 1972.
140. Srouji MN, Chatten J, David C: Pseudodiverticulitis of the appendix with neonatal Hirschsprung disease, *J Pediatr* 93:988-990, 1978.
141. Charif P: Perforated appendicitis in premature infants. A case report and review of the literature, *Johns Hopkins Med J* 125:92-94, 1969.
142. Martin LW, Glen PM: Prenatal appendiceal perforation: a case report, *J Pediatr Surg* 21:73-74, 1986.
143. Hill WB, Mason CC: Prenatal appendicitis with rupture and death, *Am J Dis Child* 29:86, 1925.
144. Corcoran WJ: Prenatal rupture of the appendix, *Am J Dis Child* 39:277, 1930.
145. Jackson WF: A case of prenatal appendicitis, *Am J Med Sci* 127:710, 1904.
146. Buntain WL: Neonatal appendicitis mistaken for necrotizing enterocolitis, *South Med J* 75:1155, 1982.
147. Wilkinson RH, Bartlett RH, Eraklis AJ: Diagnosis of appendicitis in infancy. The value of abdominal radiographs, *Am J Dis Child* 118:687-690, 1969.
148. Chang JH: The use of antibiotics in pediatric abdominal surgery, *Pediatr Infect Dis* 3:195-198, 1984.
149. Bell MJ: Peritonitis in the newborn—current concepts, *Pediatr Clin North Am* 32:1181-1201, 1985.
150. Lloyd JR: The etiology of gastrointestinal perforations in the newborn, *J Pediatr Surg* 4:77-84, 1969.
151. McDougal WS, Izant RJ Jr, Zollinger RM Jr: Primary peritonitis in infancy and childhood, *Ann Surg* 181:310-313, 1975.
152. Fonkalsrud EW, Ellis DG, Clatworthy HW Jr: Neonatal peritonitis, *J Pediatr Surg* 1:227-239, 1966.
153. Rickham PP: Peritonitis in the neonatal period, *Arch Dis Child* 30:23-31, 1955.
154. Denes J, Leb J: Neonatal peritonitis, *Acta Paediatr Acad Sci Hung* 10:297-302, 1969.
155. Daum R, Schutze U, Hill E, et al: Mortality of preoperative peritonitis in newborn infants without intestinal obstruction, *Prog Pediatr Surg* 13:267-271, 1979.
156. Schutze U, Fey KH, Hess G: Peritonitis in the neonate, in infancy and childhood {author's transl}, *MMW Munch Med Wochenschr* 116:1201-1207, 1974.
157. Prevot J, Grosdidier G, Schmitt M: Fatal peritonitis, *Prog Pediatr Surg* 13:257-266, 1979.
158. Singer B, Hammar B: Neonatal peritonitis, *S Afr Med J* 46:987-993, 1972.
159. Hensey OJ, Hart CA, Cooke RW: Serious infection in a neonatal intensive care unit: a two-year survey, *J Hyg (Lond)* 95:289-297, 1985.
160. Valdes-Dapena MA, Arey JB: The causes of neonatal mortality: an analysis of 501 autopsies on newborn infants, *J Pediatr* 77:366-375, 1970.
161. Bell MJ: Perforation of the gastrointestinal tract and peritonitis in the neonate, *Surg Gynecol Obstet* 160:20-26, 1985.
162. Mollitt DL, Tepas JJ 3rd, Talbert JL: The microbiology of neonatal peritonitis, *Arch Surg* 123:176-179, 1988.
163. Chadwick EG, Shulman ST, Yogev R: Peritonitis as a late manifestations of group B streptococcal disease in newborns, *Pediatr Infect Dis* 2:142-143, 1983.
164. Serlo W, Heikkinen E, Kouvalainen K: Group A streptococcal peritonitis in infancy, *Ann Chir Gynaecol* 74:183-184, 1985.
165. Johnson DE, Conroy MM, Foker JE, et al: *Candida* peritonitis in the newborn infants, *J Pediatr* 97:298-300, 1980.
166. Kaplan M, Eidelman AI, Dollberg L, et al: Necrotizing bowel disease with *Candida* peritonitis following severe neonatal hypothermia, *Acta Paediatr Scand* 79:876-879, 1990.
167. Butler KM, Rench MA, Baker CJ: Amphotericin b as a single agent in the treatment of systemic candidiasis in neonates, *Pediatr Infect Dis J* 9:51-56, 1990.
168. MacDonald L, Baker C, Chenoweth C: Risk factors for candidemia in a children's hospital, *Clin Infect Dis* 26:642-645, 1998.
169. Pan EY, Chen LY, Yang JZ, et al: Radiographic diagnosis of meconium peritonitis. A report of 200 cases including six fetal cases, *Pediatr Radiol* 13:199-205, 1983.
170. Holgersen LO: The etiology of spontaneous gastric perforation of the newborn: a reevaluation, *J Pediatr Surg* 16:608-613, 1981.
171. Wilson R, Kanto WP Jr, McCarthy BJ, et al: Age at onset of necrotizing enterocolitis: an epidemiologic analysis, *Pediatr Res* 16:82-85, 1982.
172. Wilson R, Kanto WP Jr, McCarthy BJ, et al: Age at onset of necrotizing enterocolitis. Risk factors in small infants, *Am J Dis Child* 136:814-816, 1982.
173. Touloukian RJ, Kadar A, Spencer RP: The gastrointestinal complications of neonatal umbilical venous exchange transfusion: a clinical and experimental study, *Pediatrics* 51:36-43, 1973.
174. Freedman RM, Ingram DL, Gross I, et al: A half century of neonatal sepsis at Yale: 1928 to 1978, *Am J Dis Child* 135:140-144, 1981.
175. Thelander HE: Perforation of the gastrointestinal tract of the newborn infant, *Am J Dis Child* 58:371, 1939.
176. Kosloske AM, Lilly JR: Paracentesis and lavage for diagnosis of intestinal gangrene in neonatal necrotizing enterocolitis, *J Pediatr Surg* 13:315-320, 1978.
177. Gerstein MC, Lindsay WK, McKendry JB: Congenital defects of lymphatics in infancy, *Pediatrics* 19:21-35, 1957.
178. Lees W, Mitchell JE: Bile peritonitis in infancy, *Arch Dis Child* 41:188-192, 1966.
179. Rosenfeld DL, Cordell CE, Jadeja N: Retrocardiac pneumomediastinum: radiographic finding and clinical implications, *Pediatrics* 85:92-97, 1990.
180. Pochacevsky R, Bryk D: New roentgenographic signs of neonatal gastric perforation, *Radiology* 102:145-147, 1972.
181. Wind ES, Pillari GP: Lucent liver in the newborn. A roentgenographic sign of pneumoperitoneum, *JAMA* 237:2218-2219, 1977.
182. Cohen MD, Weber TR, Grosfeld JL: Bowel perforation in the newborn: diagnosis with metrizamide, *Radiology* 150:65-69, 1984.
183. Thomas S, Sainsbury C, Murphy JF: Pancuronium belly, *Lancet* 2:870, 1984.
184. Ein SH, Stephens CA, Reilly BJ: The disappearance of free air after pediatric laparotomy, *J Pediatr Surg* 20:422-424, 1985.
185. Emanuel B, Zlotnik P, Raffensperger JG: Perforation of the gastrointestinal tract in infancy and childhood, *Surg Gynecol Obstet* 146:926-928, 1978.
186. Neu J, Walker WA: Necrotizing enterocolitis, *N Engl J Med* 364:255-264, 2011.
187. Patel BK, Shah JS: Necrotizing enterocolitis in very low birth weight infants: a systemic review, *ISRN Gastroenterol* 2012:562594, 2012.
188. Wu SF, Caplan M, Lin HC: Necrotizing enterocolitis: old problem with new hope, *Pediatr Neonatol* 53:158-163, 2012.
189. Dominguez KM, Moss RL: Necrotizing enterocolitis, *Clin Perinatol* 39:387-401, 2012.
190. Berman L, Moss RL: Necrotizing enterocolitis: an update, *Semin Fetal Neonatal Med* 16:145-150, 2011.
191. Kim JH: Necrotizing enterocolitis: the road to zero, *Semin Fetal Neonatal Med* 19:39-44, 2014.
192. Stoll BJ, Hansen NI, Bell EF, et al: Neonatal outcomes of extremely preterm infants from the NICHD neonatal research network, *Pediatrics* 126:443-456, 2010.
193. Horbar JD, Carpenter JH, Badger GJ, et al: Mortality and neonatal morbidity among infants 501 to 1500 grams from 2000 to 2009, *Pediatrics* 129:1019-1026, 2012.
194. de Gamarra E, Helardot P, Moriette G, et al: Necrotizing enterocolitis in full-term newborns, *Biol Neonate* 44:185-192, 1983.

195. Christensen RD, Lambert DK, Baer VL, et al: Necrotizing enterocolitis in term infants, *Clin Perinatol* 40:69-78, 2013.
196. Fitzgibbons SC, Ching Y, Yu D, et al: Mortality of necrotizing enterocolitis expressed by birth weight categories, *J Pediatr Surg* 44:1072-1075, discussion 1075-1076, 2009.
197. Morgan JA, Young L, McGuire W: Pathogenesis and prevention of necrotizing enterocolitis, *Curr Opin Infect Dis* 24:183-189, 2011.
198. Santulli TV, Schullinger JN, Heird WC, et al: Acute necrotizing enterocolitis in infancy: a review of 64 cases, *Pediatrics* 55:376-387, 1975.
199. Bhandari V, Bizzarro MJ, Shetty A, et al: Familial and genetic susceptibility to major neonatal morbidities in preterm twins, *Pediatrics* 117:1901-1906, 2006.
200. Henderson G, Craig S, Baier RJ, et al: Cytokine gene polymorphisms in preterm infants with necrotizing enterocolitis: genetic association study, *Arch Dis Child Fetal Neonatal Ed* 94:F124-F128, 2009.
201. Patole SK, de Klerk N: Impact of standardised feeding regimens on incidence of neonatal necrotising enterocolitis: a systematic review and meta-analysis of observational studies, *Arch Dis Child Fetal Neonatal Ed* 90:F147-F151, 2005.
202. Henderson G, Craig S, Brocklehurst P, et al: Enteral feeding regimens and necrotising enterocolitis in preterm infants: a multicentre case-control study, *Arch Dis Child Fetal Neonatal Ed* 94:F120-F123, 2009.
203. Morgan J, Young L, McGuire W: Slow advancement of enteral feed volumes to prevent necrotising enterocolitis in very low birth weight infants, *Cochrane Database Syst Rev*, (3), CD001241, 2013.
204. Sullivan S, Schanler RJ, Kim JH, et al: An exclusively human milk-based diet is associated with a lower rate of necrotizing enterocolitis than a diet of human milk and bovine milk-based products, *J Pediatr* 156:562-567, 2010.
205. Quigley MA, Henderson G, Anthony MY, et al: Formula milk versus donor breast milk for feeding preterm or low birth weight infants, *Cochrane Database Syst Rev*, (4)CD002971, 2007.
206. Dvorak B, Halpern MD, Holubec H, et al: Maternal milk reduces severity of necrotizing enterocolitis and increases intestinal il-10 in a neonatal rat model, *Pediatr Res* 53:426-433, 2003.
207. Claud EC, Walker WA: Hypothesis: inappropriate colonization of the premature intestine can cause neonatal necrotizing enterocolitis, *FASEB J* 15:1398-1403, 2001.
208. Morowitz MJ, Poroyko V, Caplan M, et al: Redefining the role of intestinal microbes in the pathogenesis of necrotizing enterocolitis, *Pediatrics* 125:777-785, 2010.
209. Kliegman RM: The role of clostridia in the pathogenesis of neonatal necrotizing enterocolitis. In Briellelo SP, editor: *Clostridia in gastrointestinal disease*, Boca Raton, Fla, 1985, CRC Press, pp 68-92.
210. Pedersen PV, Hansen FH, Halveg AB, et al: Necrotising enterocolitis of the newborn—is it gas-gangrene of the bowel? *Lancet* 2:715-716, 1976.
211. Westra-Meijer CM, Degener JE, Dzoljic-Danilovic G, et al: Quantitative study of the aerobic and anaerobic faecal flora in neonatal necrotising enterocolitis, *Arch Dis Child* 58:523-528, 1983.
212. Lishman AH, Al Jumaili IJ, Elshibly E, et al: *Clostridium difficile* isolation in neonates in a special care unit. Lack of correlation with necrotizing enterocolitis, *Scand J Gastroenterol* 19:441-444, 1984.
213. Cashore WJ, Peter G, Lauermann M, et al: Clostridia colonization and clostridial toxin in neonatal necrotizing enterocolitis, *J Pediatr* 98:308-311, 1981.
214. Scheifele DW, Bjornson GL: Delta toxin activity in coagulase-negative staphylococci from the bowels of neonates, *J Clin Microbiol* 26:279-282, 1988.
215. Scheifele DW, Bjornson GL, Dyer RA, et al: Delta-like toxin produced by coagulase-negative staphylococci is associated with neonatal necrotizing enterocolitis, *Infect Immun* 55:2268-2273, 1987.
216. Hoy C, Millar MR, MacKay P, et al: Quantitative changes in faecal microflora preceding necrotising enterocolitis in premature neonates, *Arch Dis Child* 65:1057-1059, 1990.
217. Richmond JA, Mikity V: Benign form of necrotizing enterocolitis, *Am J Roentgenol Radium Ther Nucl Med* 123:301-306, 1975.
218. Barnard JA, Cotton RB, Lutin W: Necrotizing enterocolitis. Variables associated with the severity of disease, *Am J Dis Child* 139:375-377, 1985.
219. Bell MJ, Ternberg JL, Feigin RD, et al: Neonatal necrotizing enterocolitis. Therapeutic decisions based upon clinical staging, *Ann Surg* 187:1-7, 1978.
220. Walsh MC, Kliegman RM: Necrotizing enterocolitis: treatment based on staging criteria, *Pediatr Clin North Am* 33:179-201, 1986.
221. Daneman A, Woodward S, de Silva M: The radiology of neonatal necrotizing enterocolitis (NEC). A review of 47 cases and the literature, *Pediatr Radiol* 7:70-77, 1978.
222. Rehan VK, Seshia MM, Johnston B, et al: Observer variability in interpretation of abdominal radiographs of infants with suspected necrotizing enterocolitis, *Clin Pediatr (Phila)* 38:637-643, 1999.
223. Mata AG, Rosengart RM: Interobserver variability in the radiographic diagnosis of necrotizing enterocolitis, *Pediatrics* 66:68-71, 1980.
224. Johnson JF, Robinson LH: Localized bowel distension in the newborn: a review of the plain film analysis and differential diagnosis, *Pediatrics* 73:206-215, 1984.
225. Leonard T Jr, Johnson JF, Pettett PG: Critical evaluation of the persistent loop sign in necrotizing enterocolitis, *Radiology* 142:385-386, 1982.
226. Frey EE, Smith W, Franken EA Jr, et al: Analysis of bowel perforation in necrotizing enterocolitis, *Pediatr Radiol* 17:380-382, 1987.
227. Kliegman RM, Fanaroff AA: Neonatal necrotizing enterocolitis: a nine-year experience. II. Outcome assessment, *Am J Dis Child* 135:608-611, 1981.
228. Kliegman RM, Fanaroff AA: Neonatal necrotizing enterocolitis: a nine-year experience, *Am J Dis Child* 135:603-607, 1981.
229. Keller MS, Chawla HS: Neonatal metrizamide gastrointestinal series in suspected necrotizing enterocolitis, *Am J Dis Child* 139:713-716, 1985.
230. Lindley S, Mollitt DL, Seibert JJ, et al: Portal vein ultrasonography in the early diagnosis of necrotizing enterocolitis, *J Pediatr Surg* 21:530-532, 1986.
231. Malin SW, Bhutani VK, Ritchie WW, et al: Echogenic intravascular and hepatic microbubbles associated with necrotizing enterocolitis, *J Pediatr* 103:637-640, 1983.
232. Caplan MS, Jilling T: New concepts in necrotizing enterocolitis, *Curr Opin Pediatr* 13:111-115, 2001.
233. Ricketts RR: The role of paracentesis in the management of infants with necrotizing enterocolitis, *Am Surg* 52:61-65, 1986.
234. Patel CC: Hematologic abnormalities in acute necrotizing enterocolitis, *Pediatr Clin North Am* 24:579-584, 1977.
235. Hutter JJ Jr, Hathaway WE, Wayne ER: Hematologic abnormalities in severe neonatal necrotizing enterocolitis, *J Pediatr* 88:1026-1031, 1976.
236. Rabinowitz SS, Dzakupsu P, Piecuch S, et al: Platelet-activating factor in infants at risk for necrotizing enterocolitis, *J Pediatr* 138:81-86, 2001.
237. Christensen RD, Rothstein G, Anstall HB, et al: Granulocyte transfusions in neonates with bacterial infection, neutropenia, and depletion of mature marrow neutrophils, *Pediatrics* 70:1-6, 1982.
238. Garcia J, Smith FR, Cucinell SA: Urinary d-lactate excretion in infants with necrotizing enterocolitis, *J Pediatr* 104:268-270, 1984.
239. Book LS, Herbst JJ, Jung AL: Carbohydrate malabsorption in necrotizing enterocolitis, *Pediatrics* 57:201-204, 1976.
240. Virnig NL, Reynolds JW: Epidemiological aspects of neonatal necrotizing enterocolitis, *Am J Dis Child* 128:186-190, 1974.
241. Kliegman RM, Walsh MC: The incidence of meningitis in neonates with necrotizing enterocolitis, *Am J Perinatol* 4:245-248, 1987.
242. Shah D, Sinn JK: Antibiotic regimens for the empirical treatment of newborn infants with necrotising enterocolitis, *Cochrane Database Syst Rev*, (8), CD007448, 2012.
243. Faix RG, Polley TZ, Grasela TH: A randomized, controlled trial of parenteral clindamycin in neonatal necrotizing enterocolitis, *J Pediatr* 112:271-277, 1988.
244. Burrington JD: Necrotizing enterocolitis in newborn infant, *Clin Perinatol* 5:29-44, 1978.
245. Ghory MJ, Sheldon CA: Newborn surgical emergencies of the gastrointestinal tract, *Surg Clin North Am* 65:1083-1098, 1985.
246. Kastenberg ZJ, Sylvester KG: The surgical management of necrotizing enterocolitis, *Clin Perinatol* 40:135-148, 2013.
247. Ein SH, Shandling B, Wesson D, et al: A 13-year experience with peritoneal drainage under local anesthesia for necrotizing enterocolitis perforation, *J Pediatr Surg* 25:1034-1036, discussion 1036-1037, 1990.
248. Egan AG, Nelson RM, Mantilla G, et al: Additional experience with routine use of oral kanamycin prophylaxis for necrotizing enterocolitis in infants under 1,500 grams, *J Pediatr* 90:331-332, 1977.



249. Grylack LJ, Scanlon JW: Oral gentamicin therapy in the prevention of neonatal necrotizing enterocolitis. A controlled double-blind trial, *Am J Dis Child* 132:1192-1194, 1978.
250. Rowley MP, Dahlenburg GW: Gentamicin in prophylaxis of neonatal necrotizing enterocolitis, *Lancet* 2:532, 1978.
251. Boyle R, Nelson JS, Stonestreet BS, et al: Alterations in stool flora resulting from oral kanamycin prophylaxis of necrotizing enterocolitis, *J Pediatr* 93:857-861, 1978.
252. Bhat AM, Meny RG: Alimentary absorption of gentamicin in preterm infants, *Clin Pediatr (Phila)* 23:683-685, 1984.
253. AlFaleh K, Anabrees J: Efficacy and safety of probiotics in preterm infants, *J Neonatal Perinatal Med* 6:1-9, 2013.
254. Chen CC, Allan Walker W: Probiotics and the mechanism of necrotizing enterocolitis, *Semin Pediatr Surg* 22:94-100, 2013.
255. Lin HC, Su BH, Chen AC, et al: Oral probiotics reduce the incidence and severity of necrotizing enterocolitis in very low birth weight infants, *Pediatrics* 115:1-4, 2005.
256. Bin-Nun A, Bromiker R, Wilschanski M, et al: Oral probiotics prevent necrotizing enterocolitis in very low birth weight neonates, *J Pediatr* 147:192-196, 2005.
257. Deshpande G, Rao S, Patole S, et al: Updated meta-analysis of probiotics for preventing necrotizing enterocolitis in preterm neonates, *Pediatrics* 125:921-930, 2010.
258. Anderson DM, Kliegman RM: The relationship of neonatal alimentary practices to the occurrence of endemic necrotizing enterocolitis, *Am J Perinatol* 8:62-67, 1991.
259. McKeown RE, Marsh TD, Amarnath U, et al: Role of delayed feeding and of feeding increments in necrotizing enterocolitis, *J Pediatr* 121:764-770, 1992.
260. Carrion V, Egan EA: Prevention of neonatal necrotizing enterocolitis, *J Pediatr Gastroenterol Nutr* 11:317-323, 1990.
261. Bohnhorst B, Muller S, Dordelmann M, et al: Early feeding after necrotizing enterocolitis in preterm infants, *J Pediatr* 143:484-487, 2003.
262. Eibl MM, Wolf HM, Furnkranz H, et al: Prophylaxis of necrotizing enterocolitis by oral IgA-IgG: review of a clinical study in low birth weight infants and discussion of the pathogenic role of infection, *J Clin Immunol* 10:72S-77S, discussion 77S-79S, 1990.
263. Eibl MM, Wolf HM, Furnkranz H, et al: Prevention of necrotizing enterocolitis in low-birth-weight infants by IgA-IgG feeding, *N Engl J Med* 319:1-7, 1988.
264. Leonidas JC, Hall RT: Neonatal pneumatosis coli: a mild form of neonatal necrotizing enterocolitis, *J Pediatr* 89:456-459, 1976.
265. Schullinger JN, Mollitt DL, Vinocur CD, et al: Neonatal necrotizing enterocolitis. Survival, management, and complications: a 25-year study, *Am J Dis Child* 135:612-614, 1981.
266. Dykes EH, Gilmour WH, Azmy AF: Prediction of outcome following necrotizing enterocolitis in a neonatal surgical unit, *J Pediatr Surg* 20:3-5, 1985.
267. Abbasi S, Pereira GR, Johnson L, et al: Long-term assessment of growth, nutritional status, and gastrointestinal function in survivors of necrotizing enterocolitis, *J Pediatr* 104:550-554, 1984.
268. Janik JS, Ein SH, Mancer K: Intestinal stricture after necrotizing enterocolitis, *J Pediatr Surg* 16:438-443, 1981.
269. Ball TI, Wyly JB: Enterocyst formation: a late complication of neonatal necrotizing enterocolitis, *AJR Am J Roentgenol* 147:806-808, 1986.
270. Walsh MC, Kliegman RM, Hack M: Severity of necrotizing enterocolitis: influence on outcome at 2 years of age, *Pediatrics* 84:808-814, 1989.
271. Leviton A, Dammann O, Engelke S, et al: The clustering of disorders in infants born before the 28th week of gestation, *Acta Paediatr* 99:1795-1800, 2010.
272. Martin CR, Dammann O, Allred EN, et al: Neurodevelopment of extremely preterm infants who had necrotizing enterocolitis with or without late bacteremia, *J Pediatr* 157:751-756, 2010.
273. Macaulay D: Acute endocarditis in infancy and early childhood, *AMA Am J Dis Child* 88:715-731, 1954.
274. Johnson DH, Rosenthal A, Nadas AS: A forty-year review of bacterial endocarditis in infancy and childhood, *Circulation* 51:581-588, 1975.
275. Johnson DH, Rosenthal A, Nadas AS: Bacterial endocarditis in children under 2 years of age, *Am J Dis Child* 129:183-186, 1975.
276. Edwards K, Ingall D, Czapek E, et al: Bacterial endocarditis in 4 young infants. Is this complication on the increase? *Clin Pediatr (Phila)* 16:607-609, 1977.
277. McGuinness GA, Schieken RM, Maguire GF: Endocarditis in the newborn, *Am J Dis Child* 134:577-580, 1980.
278. Kramer HH, Bourgeois M, Liersch R, et al: Current clinical aspects of bacterial endocarditis in infancy, childhood, and adolescence, *Eur J Pediatr* 140:253-259, 1983.
279. Oelberg DG, Fisher DJ, Gross DM, et al: Endocarditis in high-risk neonates, *Pediatrics* 71:392-397, 1983.
280. Gossius G, Gunnes P, Rasmussen K: Ten years of infective endocarditis: a clinicopathologic study, *Acta Med Scand* 217:171-179, 1985.
281. Opie GF, Fraser SH, Drew JH, et al: Bacterial endocarditis in neonatal intensive care, *J Paediatr Child Health* 35:545-548, 1999.
282. Mecrow IK, Ladusans EJ: Infective endocarditis in newborn infants with structurally normal hearts, *Acta Paediatr* 83:35-39, 1994.
283. Soo SS, Bosman DL: *Streptococcus faecalis* in neonatal infective endocarditis, *J Infect* 23:209-210, 1991.
284. Lewis IC: Bacterial endocarditis complicating septicaemia in an infant, *Arch Dis Child* 29:144-146, 1954.
285. Prandstraller D, Marata AM, Picchio FM: *Staphylococcus aureus* endocarditis in a newborn with transposition of the great arteries: successful treatment, *Int J Cardiol* 14:355-358, 1987.
286. Millard DD, Shulman ST: The changing spectrum of neonatal endocarditis, *Clin Perinatol* 15:587-608, 1988.
287. Symchych PS, Krauss AN, Winchester P: Endocarditis following intracardiac placement of umbilical venous catheters in neonates, *J Pediatr* 90:287-289, 1977.
288. Morrow WR, Haas JE, Benjamin DR: Nonbacterial endocardial thrombosis in neonates: relationship to persistent fetal circulation, *J Pediatr* 100:117-122, 1982.
289. Bergsland J, Kawaguchi A, Roland JM, et al: Mycotic aortic aneurysms in children, *Ann Thorac Surg* 37:314-318, 1984.
290. Baltimore RS: Infective endocarditis in children, *Pediatr Infect Dis J* 11:907-912, 1992.
291. Bullaboy CA, Coulson JD, Jennings RB Jr, et al: Neonatal mitral valve endocarditis: diagnosis and successful management, *Clin Pediatr (Phila)* 29:398-400, 1990.
292. Nakayama DK, O'Neill JA Jr, Wagner H, et al: Management of vascular complications of bacterial endocarditis, *J Pediatr Surg* 21:636-639, 1986.
293. Kavey RE, Frank DM, Byrum CJ, et al: Two-dimensional echocardiographic assessment of infective endocarditis in children, *Am J Dis Child* 137:851-856, 1983.
294. Perelman MJ, Sugimoto J, Arcilla RA, et al: Aortic root replacement for complicated bacterial endocarditis in an infant, *J Pediatr Surg* 24:1121-1123, 1989.
295. Tulloh RM, Silove ED, Abrams LD: Replacement of an aortic valve cusp after neonatal endocarditis, *Br Heart J* 64:204-205, 1990.
296. Favara BE, Franciosi RA, Butterfield IJ: Disseminated intravascular and cardiac thrombosis of the neonate, *Am J Dis Child* 127:197-204, 1974.
297. Begg JG: Blood-filled cysts in the cardiac valve cusps in foetal life and infancy, *J Pathol Bacteriol* 87:177-178, 1964.
298. Gersony WM, McCracken GH Jr: Purulent pericarditis in infancy, *Pediatrics* 40:224-232, 1967.
299. Wynn RJ: Neonatal *E. coli* pericarditis, *J Perinat Med* 7:23-26, 1979.
300. Cayler GC, Taybi H, Riley HD Jr, et al: Pericarditis with effusion in infants and children, *J Pediatr* 63:265-272, 1963.
301. Noren GR, Kaplan EL, Staley NA: Nonrheumatic inflammatory diseases. In Adams FH, Emmanouilides GC, editors: *Moss' heart disease in infants, children and adolescents*, Baltimore, 1983, Williams & Wilkins, pp 585-594.
302. Kanarek KS, de Brigard T, Coleman J, et al: Purulent pericarditis in a neonate, *Pediatr Infect Dis J* 10:549-550, 1991.
303. Zeevi B, Perry SB, Keane JF, et al: Interventional cardiac procedures in neonates and infants: state of the art, *Clin Perinatol* 15:633-658, 1988.
304. Chen TH, Chen CC, Hwang KP, et al: Retropharyngeal abscess with extensive mediastinitis in a 2-day-old neonate, *J Paediatr Child Health* 44:154-155, 2008.
305. Tortoriello TA, Friedman JD, McKenzie ED, et al: Mediastinitis after pediatric cardiac surgery: a 15-year experience at a single institution, *Ann Thorac Surg* 76:1655-1660, 2003.
306. Weichsel M: Mediastinitis in a newborn, *Proc Rudolf Virchow Med Soc City N Y* 22:67-73, 1963.
307. Merriman TE, Taylor RG, Natrass GR: Vertebral osteomyelitis in an infant presenting with a posterior mediastinal mass, *Pediatr Surg Int* 12:541-543, 1997.

308. Krasna IH, Rosenfeld D, Benjamin BG, et al: Esophageal perforation in the neonate: an emerging problem in the newborn nursery, *J Pediatr Surg* 22:784-790, 1987.
309. Topsis J, Kinan HY, Kandall SR: Esophageal perforation—a complication of neonatal resuscitation, *Anesth Analg* 69:532-534, 1989.
310. Coulthard M, Isaacs D: Neonatal retropharyngeal abscess, *Pediatr Infect Dis J* 10:547-549, 1991.
311. Talbert JL, Rodgers BM, Felman AH, et al: Traumatic perforation of the hypopharynx in infants, *J Thorac Cardiovasc Surg* 74:152-156, 1977.
312. Grunebaum M, Horodniceanu C, Wilunsky E, et al: Iatrogenic transmural perforation of the oesophagus in the preterm infant, *Clin Radiol* 31:257-261, 1980.
313. Azimi PH, Willert J, Petru A: Severe esophagitis in a newborn infant, *Pediatr Infect Dis J* 15:385, 1996.
314. Bittencourt AL: Congenital Chagas disease, *Am J Dis Child* 130:97-103, 1976.
315. Walsh TJ, Belitsos NJ, Hamilton SR: Bacterial esophagitis in immunocompromised patients, *Arch Intern Med* 146:1345-1348, 1986.
316. Nelson AJ: Neonatal suppurative thyroiditis, *Pediatr Infect Dis* 2:243-244, 1983.
317. Berner R, Schumacher RF, Zimmerhackl LB, et al: *Salmonella enteritidis* orchitis in a 10-week-old boy, *Acta Paediatr* 83:992-993, 1994.
318. Leake D, Leake R: Neonatal suppurative parotitis, *Pediatrics* 46:202-207, 1970.
319. David RB, O'Connell EJ: Suppurative parotitis in children, *Am J Dis Child* 119:332-335, 1970.
320. Banks WW, Handler SD, Glade GB, et al: Neonatal submandibular sialadenitis, *Am J Otolaryngol* 1:261-263, 1980.
321. Saarinen M, Takala AK, Koskenniemi E, et al: Spectrum of 2,836 cases of invasive bacterial or fungal infections in children: results of prospective nationwide five-year surveillance in Finland. Finnish Pediatric Invasive Infection Study Group, *Clin Infect Dis* 21:1134-1144, 1995.
322. Eichenfield LF, Frieden IJ, Esterly NB: *Neonatal dermatology*, ed 2, Philadelphia, 2008, Saunders.
323. Swartz MN, Weinberg AN: Bacterial diseases with cutaneous involvement. In Fitzpatrick TB, editor: *Dermatology in general medicine*, New York, 1971, McGraw Hill.
324. Frieden IJ: Blisters and pustules in the newborn, *Curr Probl Pediatr* 19:549-614, 1989.
325. Weinberg S, Prose NS, Kristal L: *Color atlas of pediatric dermatology*, ed 4, New York, 2011, McGraw Hill.
326. Speert H: Circumcision of the newborn; an appraisal of its present status, *Obstet Gynecol* 2:164-172, 1953.
327. Annobil SH, al-Hilfi A, Kazi T: Primary tuberculosis of the penis in an infant, *Tubercle* 71:229-230, 1990.
328. Cleary TG, Kohl S: Overwhelming infection with group B beta-hemolytic *Streptococcus* associated with circumcision, *Pediatrics* 64:301-303, 1979.
329. Annunziato D, Goldblum LM: Staphylococcal scalded skin syndrome. A complication of circumcision, *Am J Dis Child* 132:1187-1188, 1978.
330. Woodside JR: Necrotizing fasciitis after neonatal circumcision, *Am J Dis Child* 134:301-302, 1980.
331. Stranko J, Ryan ME, Bowman AM: Impetigo in newborn infants associated with a plastic bell clamp circumcision, *Pediatr Infect Dis* 5:597-599, 1986.
332. Siddiqi SF, Taylor PM: Necrotizing fasciitis of the scalp. A complication of fetal monitoring, *Am J Dis Child* 136:226-228, 1982.
333. Okada DM, Chow AW, Bruce VT: Neonatal scalp abscess and fetal monitoring: factors associated with infection, *Am J Obstet Gynecol* 129:185-189, 1977.
334. Cordero L, Anderson CW, Zuspan FP: Scalp abscess: a benign and infrequent complication of fetal monitoring, *Am J Obstet Gynecol* 146:126-130, 1983.
335. Wagoner MM, Rychek RR, Yee RB, et al: Septic dermatitis of the neonatal scalp and maternal endomyometritis with intrapartum internal fetal monitoring, *Pediatrics* 74:81-85, 1984.
336. Brook I, Frazier EH: Microbiology of scalp abscess in newborns, *Pediatr Infect Dis J* 11:766-768, 1992.
337. Bogdan JC, Rapkin RH: Clostridia infection in the newborn, *Pediatrics* 58:120-122, 1976.
338. Sarkany I, Gaylarde CC: Skin flora of the newborn, *Lancet* 1:589-590, 1967.
339. Sarkany I, Arnold L: The effect of single and repeated applications of hexachlorophane on the bacterial flora of the skin of the newborn, *Br J Dermatol* 82:261-267, 1970.
340. Fortunov RM, Hulten KG, Hammerman WA, et al: Community-acquired *Staphylococcus aureus* infections in term and near-term previously healthy neonates, *Pediatrics* 118:874-881, 2006.
341. Zafar AB, Butler RC, Reese DJ, et al: Use of 0.3% triclosan (bactistat) to eradicate an outbreak of methicillin-resistant *Staphylococcus aureus* in a neonatal nursery, *Am J Infect Control* 23:200-208, 1995.
342. Thompson DJ, Gezon HM, Rogers KD, et al: Excess risk of staphylococcal infection and disease in newborn males, *Am J Epidemiol* 84:314-328, 1966.
343. Rudoy RC, Nelson JD: Breast abscess during the neonatal period. A review, *Am J Dis Child* 129:1031-1034, 1975.
344. Reboli AC, John JF Jr, Levkoff AH: Epidemic methicillin-gentamicin-resistant *Staphylococcus aureus* in a neonatal intensive care unit, *Am J Dis Child* 143:34-39, 1989.
345. Purcell K, Fergie J: Epidemic of community-acquired methicillin-resistant *Staphylococcus aureus* infections: a 14-year study at Driscoll Children's Hospital, *Arch Pediatr Adolesc Med* 159:980-985, 2005.
346. Evans HE, Akpata SO, Baki A, et al: Flora in newborn infants: annual variation in prevalence of *Staphylococcus aureus*, *Escherichia coli*, and streptococci, *Arch Environ Health* 26:275-276, 1973.
347. Starr HJ, Holliday PB Jr: Erythema multiforme as a manifestation of neonatal septicemia, *J Pediatr* 38:315-319, 1951.
348. Washington JL, Fowler RE, Guarino GJ: Erythema multiforme in a premature infant associated with sepsis due to *Pseudomonas*, *Pediatrics* 39:120-122, 1967.
349. Belgaumkar TK: Letter: Impetigo neonatorum congenita due to group B beta-hemolytic *Streptococcus* infection, *J Pediatr* 86:982-983, 1975.
350. Halal F, Delorme L, Brazeau M, et al: Congenital vesicular eruption caused by *Haemophilus influenzae* type b, *Pediatrics* 62:494-496, 1978.
351. Kline A, O'Donnell E: Group B streptococcus as a cause of neonatal bullous skin lesions, *Pediatr Infect Dis J* 12:165-166, 1993.
352. Bray DA: Ecthyma gangrenosum: full thickness nasal slough, *Arch Otolaryngol* 98:210-211, 1973.
353. Heffner RW, Smith GF: Ecthyma gangrenosum in *Pseudomonas* septicemia, *AMA J Dis Child* 99:524-528, 1960.
354. Basu S, Kumar A: Ecthyma gangrenosum in a premature low-birth-weight newborn, *J Wound Care* 20:587-589, 2011.
355. Pathak A, Singh P, Yadav Y, et al: Ecthyma gangrenosum in a neonate: not always *Pseudomonas*, *BMJ Case Rep* 27:2013, 2013. pii:bc2013009287.
356. Baley JE, Silverman RA: Systemic candidiasis: cutaneous manifestations in low birth weight infants, *Pediatrics* 82:211-215, 1988.
357. Agarwal S, Sharma M, Mehndirata V: Solitary ecthyma gangrenosum (EG)-like lesion consequent to *Candida albicans* in a neonate, *Indian J Pediatr* 74:582-584, 2007.
358. Nakwan N, Wannaro J, Dissaneevate P, et al: Septicemia, meningitis, and skull osteomyelitis complicating infected cephalhematoma caused by ESBL-producing *Escherichia coli*, *Southeast Asian J Trop Med Public Health* 42:148-151, 2011.
359. Mohon RT, Mehalic TF, Grimes CK, et al: Infected cephalhematoma and neonatal osteomyelitis of the skull, *Pediatr Infect Dis* 5:253-256, 1986.
360. Cohen SM, Miller BW, Orris HW: Meningitis complicating cephalhematoma, *J Pediatr* 30:327-329, 1947.
361. Ellis SS, Montgomery JR, Wagner M, et al: Osteomyelitis complicating neonatal cephalhematoma, *Am J Dis Child* 127:100-102, 1974.
362. Walsh M, McIntosh K: Neonatal mastitis, *Clin Pediatr (Phila)* 25:395-399, 1986.
363. Brook I: The aerobic and anaerobic microbiology of neonatal breast abscess, *Pediatr Infect Dis J* 10:785-786, 1991.
364. Cushing AH: Omphalitis: a review, *Pediatr Infect Dis* 4:282-285, 1985.
365. McKenna H, Johnson D: Bacteria in neonatal omphalitis, *Pathology* 9:111-113, 1977.
366. Mason WH, Andrews R, Ross LA, et al: Omphalitis in the newborn infant, *Pediatr Infect Dis J* 8:521-525, 1989.
367. Geil CC, Castle WK, Mortimer EA Jr: Group A streptococcal infections in newborn nurseries, *Pediatrics* 46:849-854, 1970.
368. Pandey A, Gangopadhyay AN, Upadhyaya VD: Necrotising fasciitis in children and neonates: current concepts, *J Wound Care* 17:5-10, 2008.
369. Hsieh WS, Yang PH, Chao HC, et al: Neonatal necrotizing fasciitis: a report of three cases and review of the literature, *Pediatrics* 103:e53, 1999.

370. Goldberg GN, Hansen RC, Lynch PJ: Necrotizing fasciitis in infancy: report of three cases and review of the literature, *Pediatr Dermatol* 2:55-63, 1984.
371. Lang ME, Vaudry W, Robinson JL: Case report and literature review of late-onset group B streptococcal disease manifesting as necrotizing fasciitis in preterm infants: is this a new syndrome? *Clin Infect Dis* 37:e132-135, 2003.
372. Brook I: Microbiology of necrotizing fasciitis associated with omphalitis in the newborn infant, *J Perinatol* 18:28-30, 1998.
373. Arditi M, Yogev R: Perirectal abscess in infants and children: report of 52 cases and review of literature, *Pediatr Infect Dis J* 9:411-415, 1990.
374. Krieger RW, Chusid MJ: Perirectal abscess in childhood. A review of 29 cases, *Am J Dis Child* 133:411-412, 1979.
375. Victorin L: An epidemic of otitis in newborns due to infection with *Pseudomonas aeruginosa*, *Acta Paediatr Scand* 56:344-348, 1967.
376. LaVoo EJ, Paller AS: Common skin problems during the first year of life, *Pediatr Clin North Am* 41:1105-1119, 1994.
377. Glover MT, Atherton DJ, Levinsky RJ: Syndrome of erythroderma, failure to thrive, and diarrhea in infancy: a manifestation of immunodeficiency, *Pediatrics* 81:66-72, 1988.
378. Zeb A, Darmstadt GL: Sclerema neonatorum: a review of nomenclature, clinical presentation, histological features, differential diagnoses and management, *J Perinatol* 28:453-460, 2008.
379. Berk DR, Bayliss SJ: Milia: a review and classification, *J Am Acad Dermatol* 59:1050-1063, 2008.
380. Gordon I: Miliary sebaceous cysts and blisters in the healthy newborn, *Arch Dis Child* 24:286-288, 1949.
381. Morgan AJ, Steen CJ, Schwartz RA, et al: Erythema toxicum neonatorum revisited, *Cutis* 83:13-16, 2009.
382. Schwartz RA, Janniger CK: Erythema toxicum neonatorum, *Cutis* 58:153-155, 1996.
383. Merlob P, Metzker A, Reisner SH: Transient neonatal pustular melanosis, *Am J Dis Child* 136:521-522, 1982.
384. Lucky AW, McGuire JS: Infantile acropustulosis with eosinophilic pustules, *J Pediatr* 100:428-429, 1982.
385. Murphy WF, Langley AL: Common bullous lesions—presumably self-inflicted—occurring in utero in the newborn infant, *Pediatrics* 32:1099-1101, 1963.
386. Ravanfar P, Wallace JS, Pace NC: Diaper dermatitis: a review and update, *Curr Opin Pediatr* 24:472-479, 2012.
387. Erasala GN, Romain C, Merlay I: Diaper area and disposable diapers, *Curr Probl Dermatol* 40:83-89, 2011.
388. American Academy of Pediatrics: *American College of Obstetricians and Gynecologists: Guidelines for perinatal care*, ed 7. Chicago, 2013, American Academy of Pediatrics.
389. Gladstone IM, Clapper L, Thorp JW, et al: Randomized study of six umbilical cord care regimens. Comparing length of attachment, microbial control, and satisfaction, *Clin Pediatr (Phila)* 27:127-129, 1988.
390. Imdad A, Bautista RM, Senen KA, et al: Umbilical cord antiseptics for preventing sepsis and death among newborns, *Cochrane Database Syst Rev*, (5), CD008635, 2013.
391. Gezon HM, Schaberg MJ, Klein JO: Concurrent epidemics of *Staphylococcus aureus* and group A *Streptococcus* disease in a newborn nursery. Control with penicillin G and hexachlorophene bathing, *Pediatrics* 51:383-390, 1973.
392. Seeberg S, Brinkhoff B, John E, et al: Prevention and control of neonatal pyoderma with chlorhexidine, *Acta Paediatr Scand* 73:498-504, 1984.
393. de Toledo AR, Chandler JW: Conjunctivitis of the newborn, *Infect Dis Clin North Am* 6:807-813, 1992.
394. Whitcher JP: Neonatal ophthalmia: have we advanced in the last 20 years? *Int Ophthalmol Clin* 30:39-41, 1990.
395. Hedberg K, Ristinen TL, Soler JT, et al: Outbreak of erythromycin-resistant staphylococcal conjunctivitis in a newborn nursery, *Pediatr Infect Dis J* 9:268-273, 1990.
396. Prentice MJ, Hutchinson GR, Taylor-Robinson D: A microbiological study of neonatal conjunctivae and conjunctivitis, *Br J Ophthalmol* 61:601-607, 1977.
397. Sandstrom KI, Bell TA, Chandler JW, et al: Microbial causes of neonatal conjunctivitis, *J Pediatr* 105:706-711, 1984.
398. Regev-Yochay G, Rubinstein E, Barzilai A, et al: Methicillin-resistant *Staphylococcus aureus* in neonatal intensive care unit, *Emerg Infect Dis* 11:453-456, 2005.
399. Rutar T: Vertically acquired community methicillin-resistant *Staphylococcus aureus* dacryocystitis in a neonate, *J AAPOS* 13:79-81, 2009.
400. Kim JH, Kim MK, Oh JY, et al: Outbreak of gram-positive bacterial keratitis associated with epidemic keratoconjunctivitis in neonates and infants, *Eye (Lond)* 23:1059-1065, 2009.
401. Stenson S, Newman R, Fedukowicz H: Conjunctivitis in the newborn: observations on incidence, cause, and prophylaxis, *Ann Ophthalmol* 13:329-334, 1981.
402. Burns RP, Rhodes DHJ: *Pseudomonas* eye infection as a cause of death in premature infants, *Arch Ophthalmol* 65:517-525, 1961.
403. Lohrer R, Belohradsky BH: Bacterial endophthalmitis in neonates, *Eur J Pediatr* 146:354-359, 1987.
404. Christensen GD, Korones SB, Reed L, et al: Epidemic *Serratia marcescens* in a neonatal intensive care unit: importance of the gastrointestinal tract as a reservoir, *Infect Control* 3:127-133, 1982.
405. Nishida H, Risemberg HM: Silver nitrate ophthalmic solution and chemical conjunctivitis, *Pediatrics* 56:368-373, 1975.
406. Kripke SS, Golden B: Neonatal inclusion conjunctivitis. A report of three cases and a discussion of differential diagnosis and treatment, *Clin Pediatr (Phila)* 11:261-263, 1972.
407. Pickering LK, editor: *Red book: report of the Committee of Infectious Diseases*, Elk Grove Village, Ill, 2012, American Academy of Pediatrics.