

Brain Abscess Caused by *Streptococcus pyogenes* in a Previously Healthy Child[∇]

Walter Dehority,^{1,4*} Satoshi Uchiyama,² Arya Khosravi,² and Victor Nizet^{2,3,4}

Divisions of Pediatric Infectious Diseases¹ and Pharmacology and Drug Discovery,² School of Medicine, and Skaggs School of Pharmacy and Pharmaceutical Sciences,³ University of California, San Diego, and Rady Children's Hospital & Health Center,⁴ San Diego, California

Received 20 August 2006/Returned for modification 29 September 2006/Accepted 11 October 2006

Responsible for many childhood diseases, group A *Streptococcus* (GAS) is a rare cause of central nervous system infections. We report the case of a previously healthy boy with brain abscesses caused by M/emm type 12 GAS and review the case in the context of the published literature and recent epidemiological data.

CASE REPORT

A 17-month-old previously healthy Caucasian boy was in his usual state of good health until 2 weeks prior to admission, when he was diagnosed with acute otitis media (OM) and began a 7-day course of oral amoxicillin. One week prior to admission, he developed rhinorrhea and a nonproductive cough, followed 2 days later by the onset of intermittent emesis. On the day of admission, he was noted to be lethargic and had stopped walking and talking and was brought by his parents to an outside emergency department. No known ill contacts were reported, and no significant history of medical problems in the family was volunteered.

While in the emergency department, the patient suffered a generalized tonic-clonic seizure, followed by decorticate posturing. Physical exam at this time was also notable for the absence of fever and a concern of bilateral papilledema. A complete blood count with differential revealed a white blood cell count of 42,000/mm³, with 76% neutrophils, 2% band forms, 16% lymphocytes, 5% monocytes, and 1% eosinophils. C-reactive protein was 2.3 mg/dl. Chemistry and liver function panels were normal. The patient was intubated for airway protection and transferred to the pediatric intensive care unit at our children's hospital. A computerized tomography (CT) scan of the head with intravenous contrast revealed large abscess collections in the right posterior parietal (5.9 by 2.7 cm) and left temporal (2.2 by 1.9 cm) lobes (Fig. 1). The patient was treated empirically with intravenous meropenem, vancomycin, and a tapering dosage of dexamethasone. An echocardiogram was normal.

On the second hospital day, the patient underwent neurosurgical drainage of his abscesses. Intraoperative samples were collected and transported appropriately for aerobic

and anaerobic culture, and gram staining of the abscess fluid revealed gram-positive cocci in pairs and short chains. Cultures from each abscess grew beta-hemolytic *Streptococcus pyogenes* (group A streptococcus [GAS]) as the sole isolate; no anaerobes were identified. On hospital day 3, vancomycin was discontinued and intravenous penicillin G was initiated. Blood and urine cultures from admission demonstrated no growth. An immunological evaluation revealed normal immunoglobulin levels, normal total and alternate complement activity (CH50/AH50), normal pneumococcal and tetanus antibody titers, a normal dihydrorhodamine assay (to exclude chronic granulomatous disease), and a nonreactive human immunodeficiency virus enzyme-linked immunosorbent assay. On the 10th hospital day, the patient was discharged home to complete a 6-week course of parental antibiotic therapy with ceftriaxone. Repeat CT scan at 4 weeks of therapy demonstrated almost complete resolution of his abscesses, and the patient eventually made a complete recovery. Genetic analysis by the Centers for Disease Control and Prevention (CDC) *Streptococcus* Laboratory (B. Beall, director) revealed the GAS isolate to be M/emm type 12, T type 12. *emm* genotyping was performed by the method of Li et al. (5), and T typing was performed by the method of Johnson and Kaplan (7).

Despite its ubiquity and well-established invasive disease potential, GAS has rarely been described as a pathogen in central nervous system (CNS) infections. A PUBMED search of the English language literature revealed four previous reports of brain abscess caused by GAS in any age group (2, 4, 6, 9) (Table 1), while a 2001 review of GAS meningitis in children described only 29 well-documented cases in the world's literature since 1976 (11). The clinical presentation and laboratory manifestations of CNS infections produced by GAS do not appear to differ from those of other, more common CNS pathogens (2, 4, 6, 9, 11).

The epidemiology of invasive GAS infection in the United States is studied by the CDC Active Bacterial Core surveillance (ABCs), part of the Emerging Infections

* Corresponding author. Mailing address: Department of Infectious Diseases, Rady Children's Hospital and Health Center, San Diego, 3020 Children's Way, MC 5041, San Diego, CA 92123. Phone: (858) 576-1700, ext. 7785. Fax: (858) 571-3372. E-mail: wdehority@ucsd.edu.

[∇] Published ahead of print on 25 October 2006.

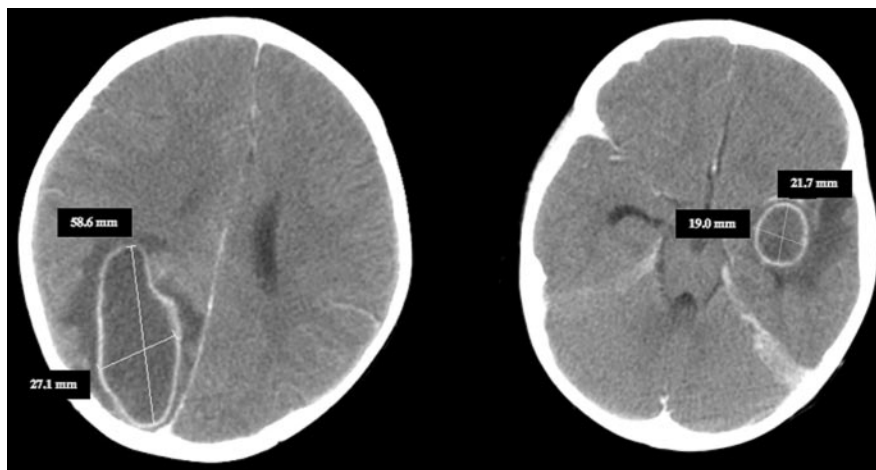


FIG. 1. Head CT scan with intravenous contrast performed on the day of admission. The image on the left shows an abscess collection measuring 58.6 by 27.1 mm in the right posterior parietal region; the image on the right reveals an abscess measuring 21.7 by 19.0 mm in the left temporal lobe.

Program Network (<http://www.cdc.gov/ncidod/dbmd/abs>). From 3,234 cases of sterile-site infections registered between 2002 and 2004 from areas including all or parts of 10 states, 35 (1.1%) carry the clinical description of meningitis, and in 23 (0.7%) of these cases GAS was isolated from the cerebrospinal fluid (B. Beall, CDC, personal communication). Of these, 20/35 (57%) were in males, 17/35 (49%) were in pediatric patients, and 6/35 (17%) were in patients <2 years of age. The GAS strain producing the brain abscesses in our reported case belongs to M/emm type 12. In the 2002 to 2004 ABCs data, M/emm type 12 is among the four most common causes of invasive GAS infection (8.7% of genotyped isolates), along with M/emm types 1 (23%), 3 (8.9%), and 28 (9.1%). Of the 28 genotyped GAS isolates obtained within this time period (blood or cerebrospinal fluid) from patients with meningitis, 3 (11%) were M/emm type 12, which is tied with M/emm type 28 as the type second most commonly associated with CNS infection, behind M/emm type 1 (7 cases, 25%).

The relative absence of GAS in the reported brain abscess literature may reflect a basic observation regarding the microbiology of CNS infections in children outside the neonatal period. In previously healthy children, the microbiology of brain abscess parallels, to a great extent, that of OM and sinusitis. Antecedent OM or chronic sinusitis is reported in 23 to 31% of pediatric brain abscesses (3, 10). In contrast to pharyngitis, GAS is a much less common cause of child-

hood OM and sinusitis, accounting for only ~2% of isolates from cultures collected from middle ear or sinus aspirates (1, 8). Nevertheless, antecedent OM or sinusitis is reported in 24% of children with GAS meningitis (11), and both our patient and one of the four earlier reported cases of GAS brain abscess (2) carried an antecedent diagnosis of OM. An alternative etiology for our patient's condition would be blood-brain barrier penetration by the GAS pathogen during the course of bacteremia, akin to the mechanism of pathogenesis accepted for the more common streptococcal CNS pathogen of early childhood *Streptococcus pneumoniae*.

The absence of neurological sequelae in all five reported cases of GAS brain abscess (Table 1) contrasts with reports of brain abscess secondary to other pathogens in children and adults. Persistent neurological sequelae were reported in 44 to 65% of children with brain abscesses in the larger published series (3, 10, 12). Though the small number of brain abscesses caused by GAS reported in the literature prevents definitive conclusions, such abscesses may carry a better prognosis than those caused by more common CNS pathogens.

We thank ABCs staff at CDC for epidemiologic data. We also thank the CDC *Streptococcus* Laboratory (director, Bernard Beall) for providing the emm and T types of this isolate.

TABLE 1. Summary of five reported cases of GAS brain abscess

Age (yr)	M/emm type	T type	Signs and symptoms	Predisposing factor	Sequelae	Reference
12	M1	T1	Headache, emesis, fever, photophobia	None	None	4
48	M22	T12	Headache, seizure, slurred speech, left arm and face paresis	None	None	9
10	NA ^a	NA	Headache, emesis	None	None	6
22	M5	NA	Headache, emesis, fever	Acute OM	None	2
1.5	M12	T12	Emesis, lethargy	Acute OM	None	This report

^a NA, not available.

REFERENCES

1. **Bluestone, C. D., J. S. Stephenson, and L. M. Martin.** 1992. Ten-year review of otitis media pathogens. *Pediatr. Infect. Dis. J.* **11**:S7–S11.
2. **Crum, N. F.** 2004. Group A streptococcal brain abscess. *Scand. J. Infect. Dis.* **36**:238–239.
3. **Jadavji, T., R. P. Humphreys, and C. G. Prober.** 1985. Brain abscesses in infants and children. *Pediatr. Infect. Dis. J.* **4**:394–398.
4. **Jagdis, F.** 1988. Group A streptococcal meningitis and brain abscess. *Pediatr. Infect. Dis. J.* **7**:885–886.
5. **Johnson, D. R., and E. L. Kaplan.** 1993. A review of the correlation of T-agglutination patterns and M-protein typing and opacity factor production in the identification of group A streptococci. *J. Med. Microbiol.* **38**:311–315.
6. **Khan, M. A., G. M. Viagappan, and J. Andrews.** 2001. Group A streptococcal brain abscess. *Scand. J. Infect. Dis.* **33**:159.
7. **Li, Z., V. Sakota, D. Jackson, A. R. Frankin, and B. Beall, for the Active Bacterial Core Surveillance/Emerging Infections Program Network.** 2003. Array of M protein gene subtypes in 1064 recent invasive group A streptococcus isolates recovered from the active bacterial core surveillance. *J. Infect. Dis.* **188**:1587–1592.
8. **Orobello, P. W., Jr., R. I. Park, L. J. Belcher, P. Eggleston, H. M. Lederman, J. R. Banks, J. F. Modlin, and R. M. Naclerio.** 1991. Microbiology of chronic sinusitis in children. *Arch. Otolaryngol. Head Neck Surg.* **117**:980–983.
9. **Ralph, E., and G. Shoemaker.** 1999. Group A streptococcal brain abscess. *Scand. J. Infect. Dis.* **31**:206–207.
10. **Saez-Llorens, X. J., M. A. Umana, C. M. Odio, G. H. McCracken, Jr., and J. D. Nelson.** 1989. Brain abscess in infants and children. *Pediatr. Infect. Dis. J.* **8**:449–458.
11. **Shetty, A. K., L. R. Frankel, Y. Maldonado, D. A. Falco, and D. B. Lewis.** 2001. Group A streptococcal meningitis: report of a case and review of literature since 1976. *Pediatr. Emerg. Care* **17**:430–434.
12. **Tseng, J. H., and M. Y. Tseng.** 2006. Brain abscess in 142 patients: factors influencing outcome and mortality. *Surg. Neurol.* **65**:557–562.